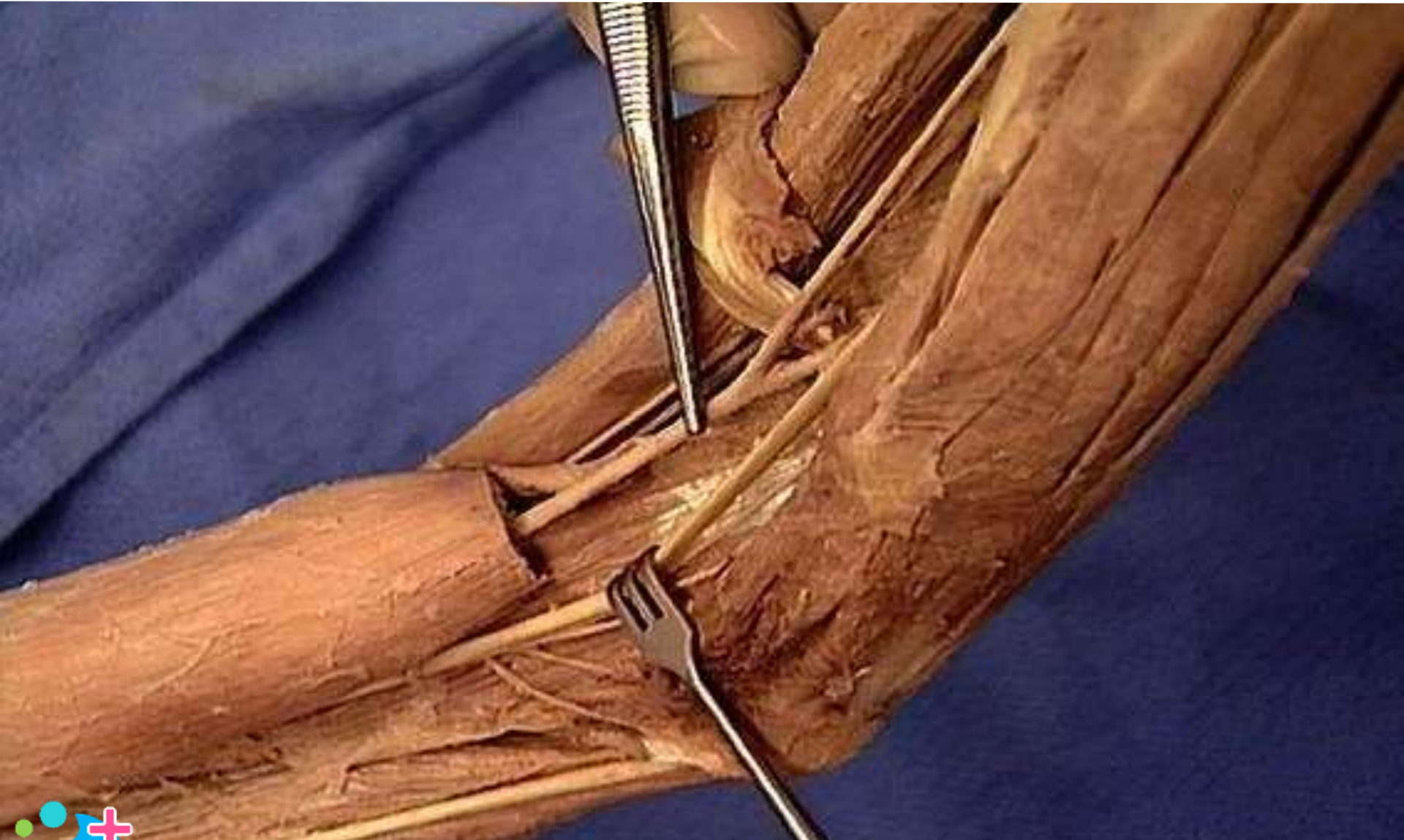

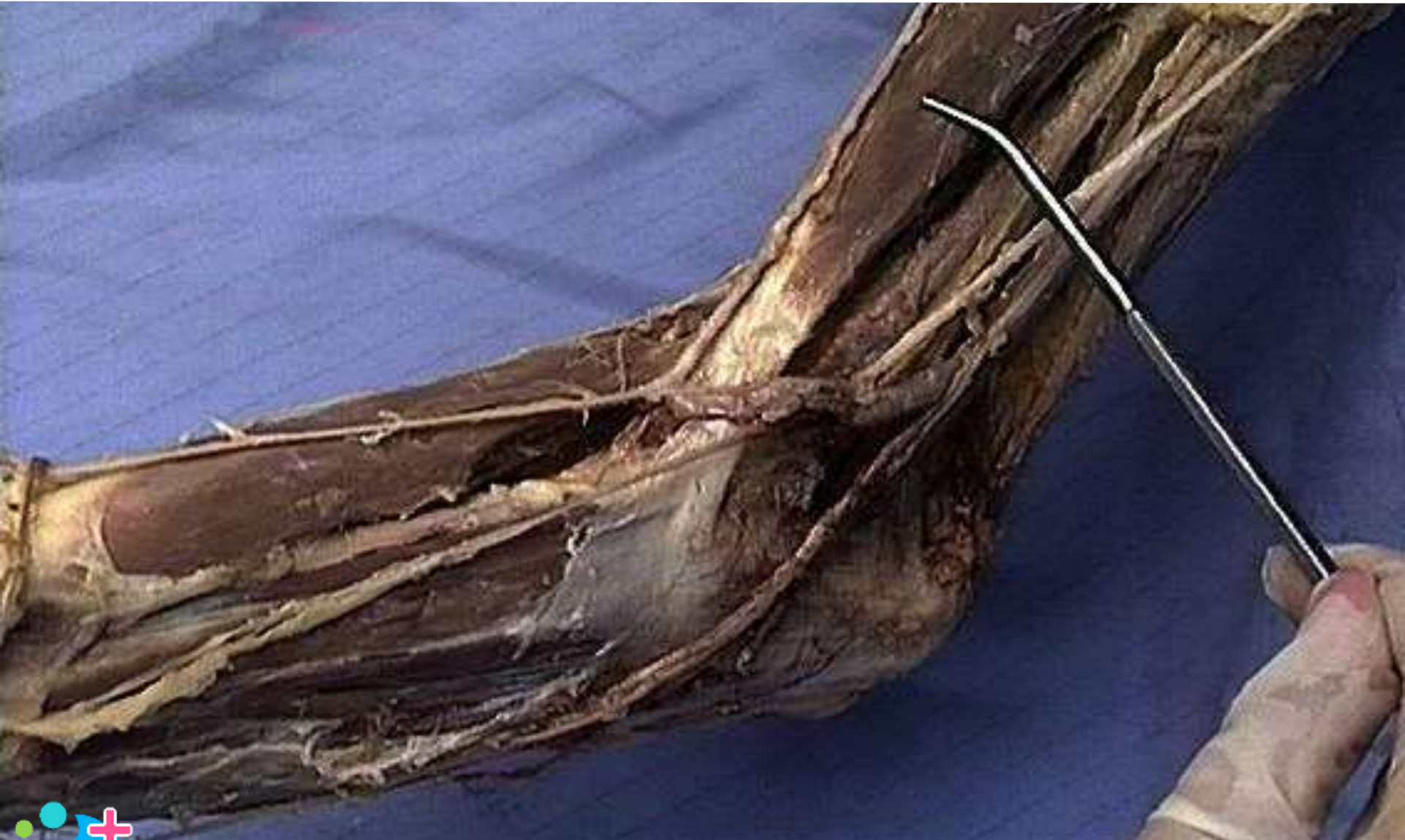Anatomy Dissection Pictures



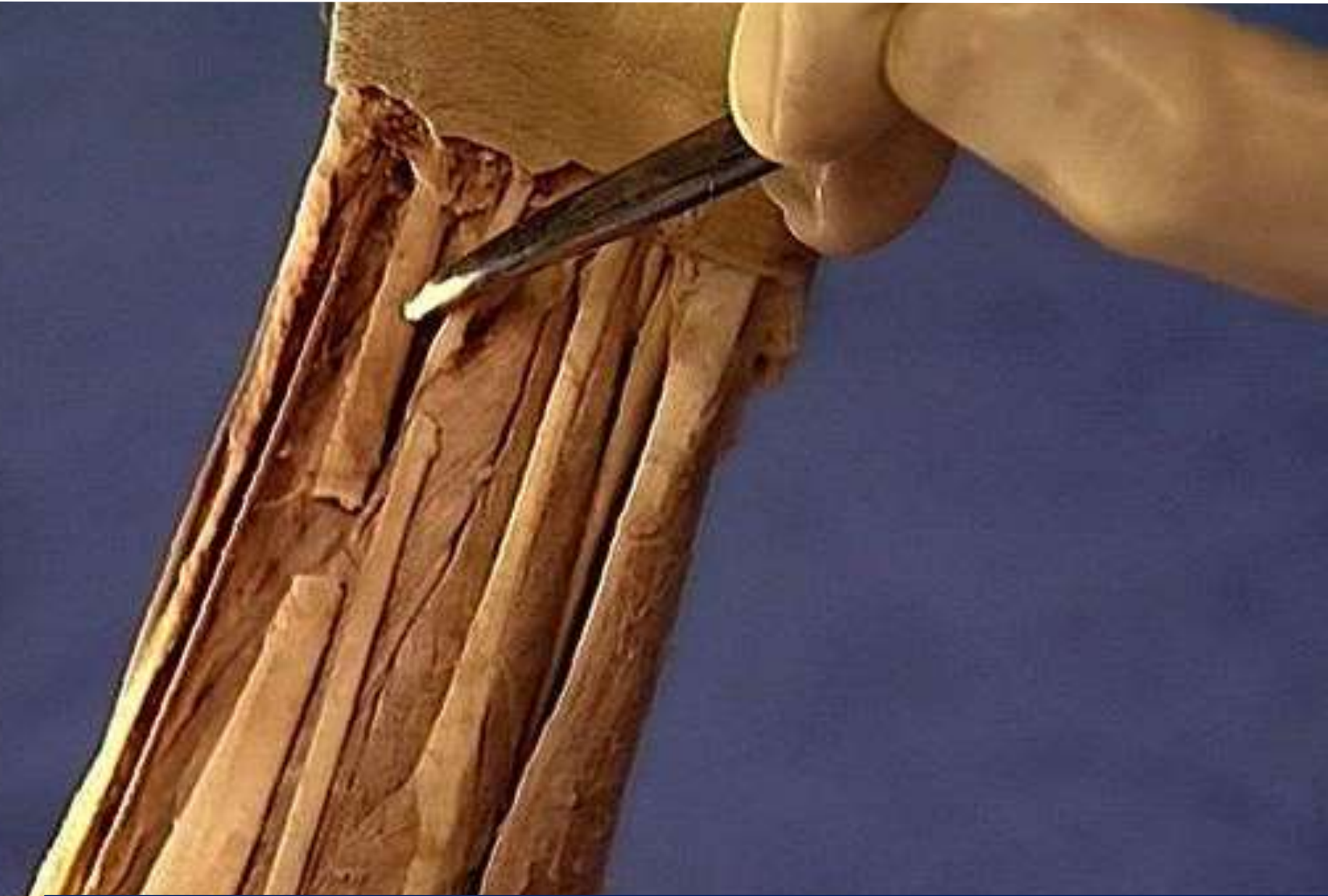
Brachial artery



Biceps brachii



Flexor carpi radialis



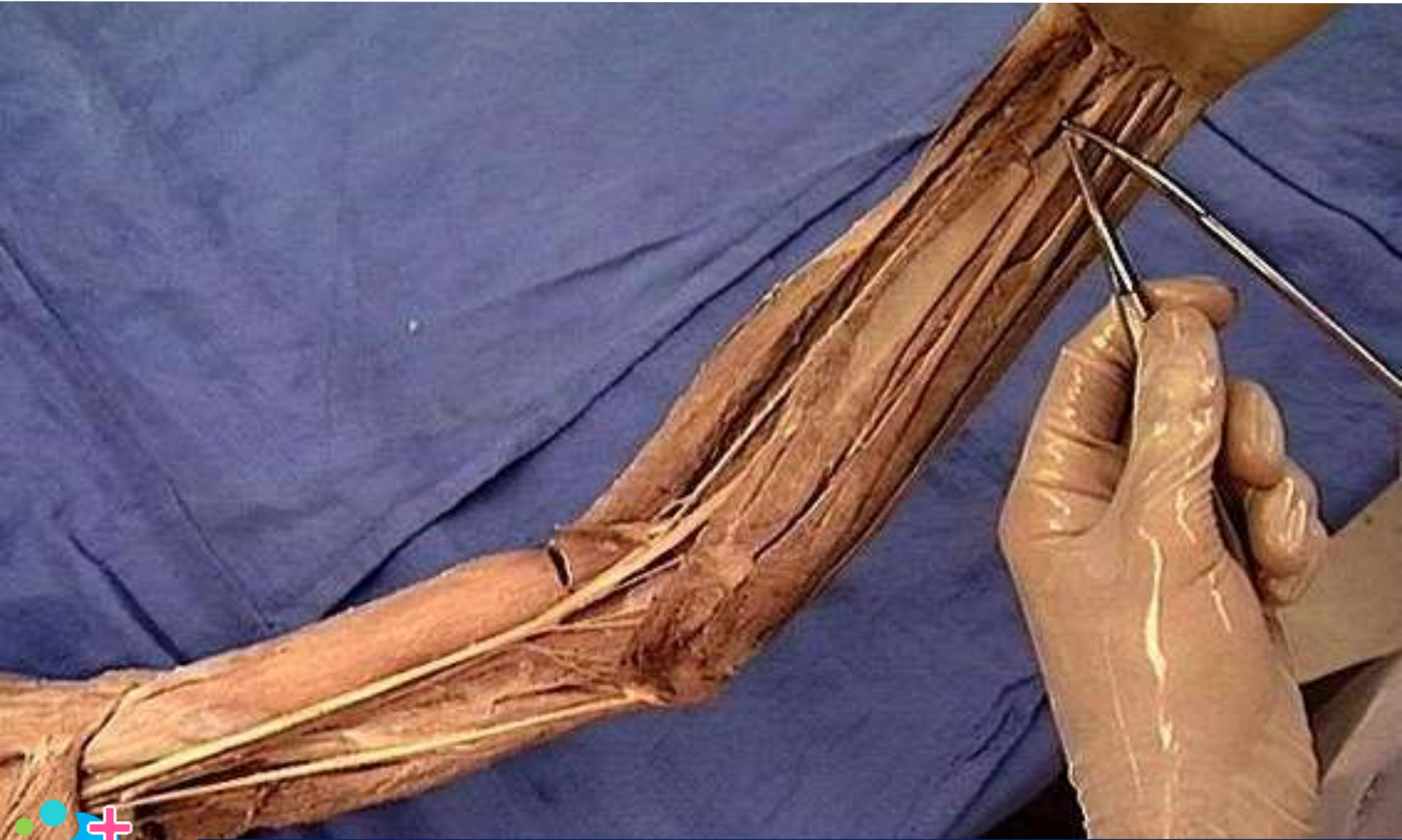Superior ulnar collateral artery



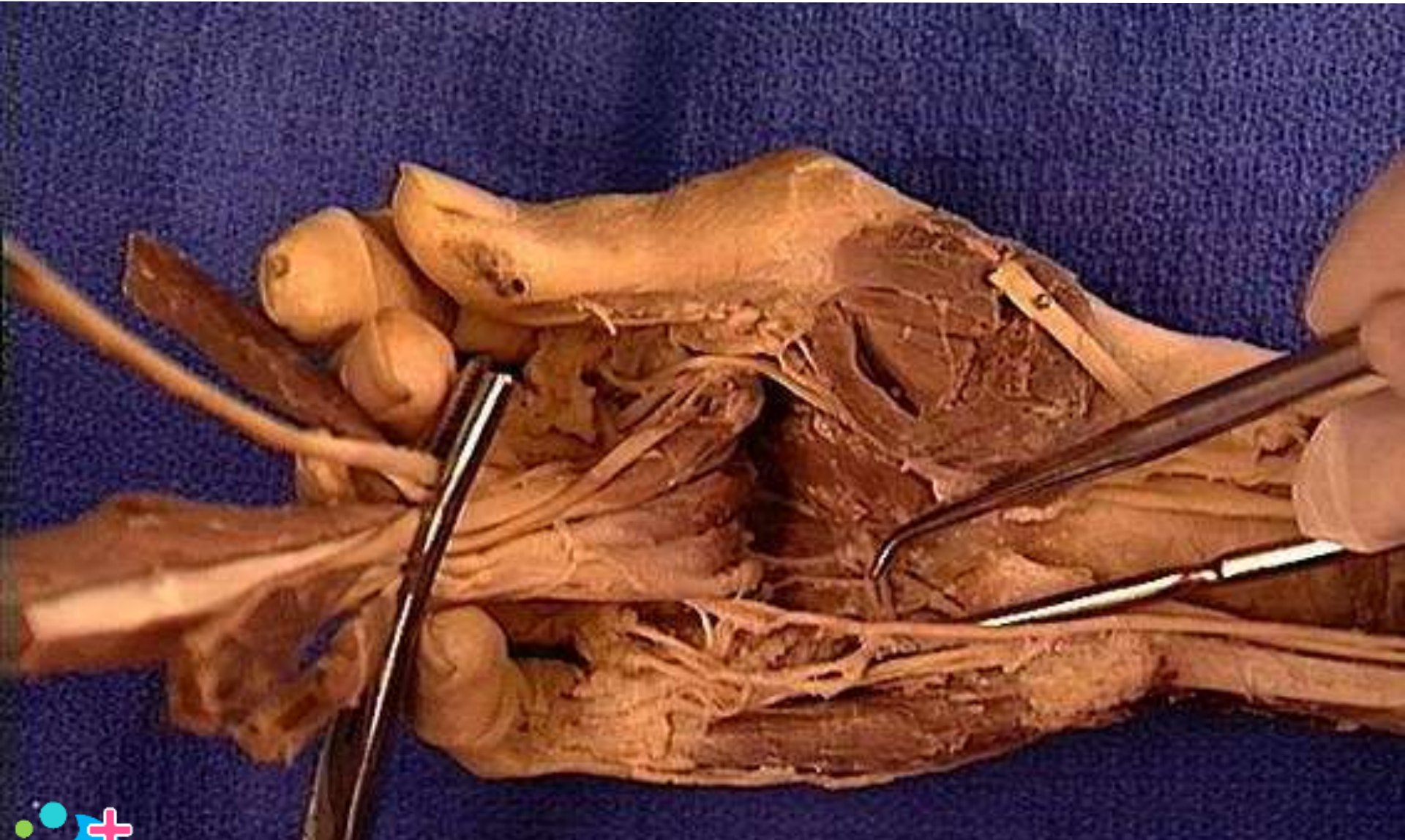
Circumflex scapular artery



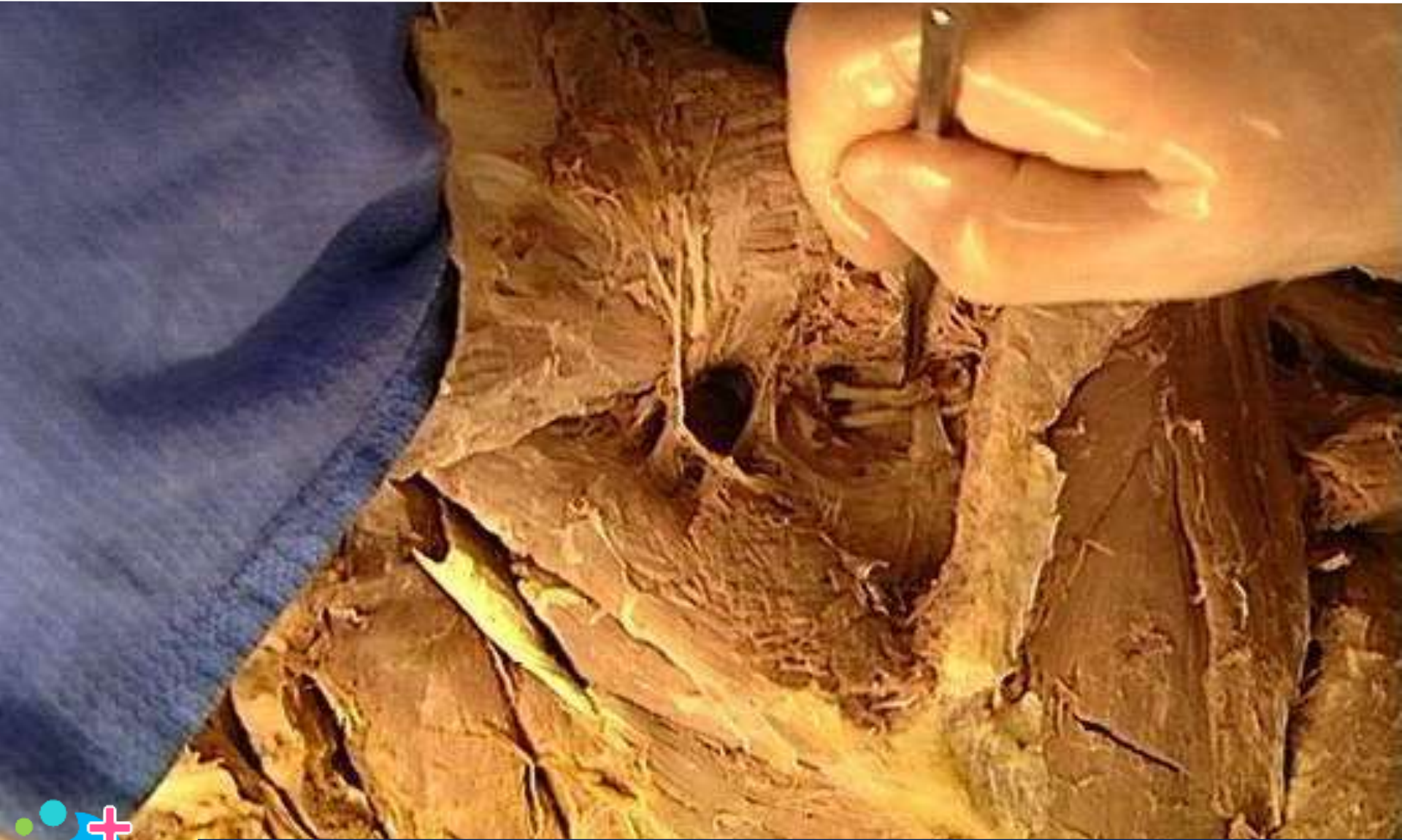Palmaris longus



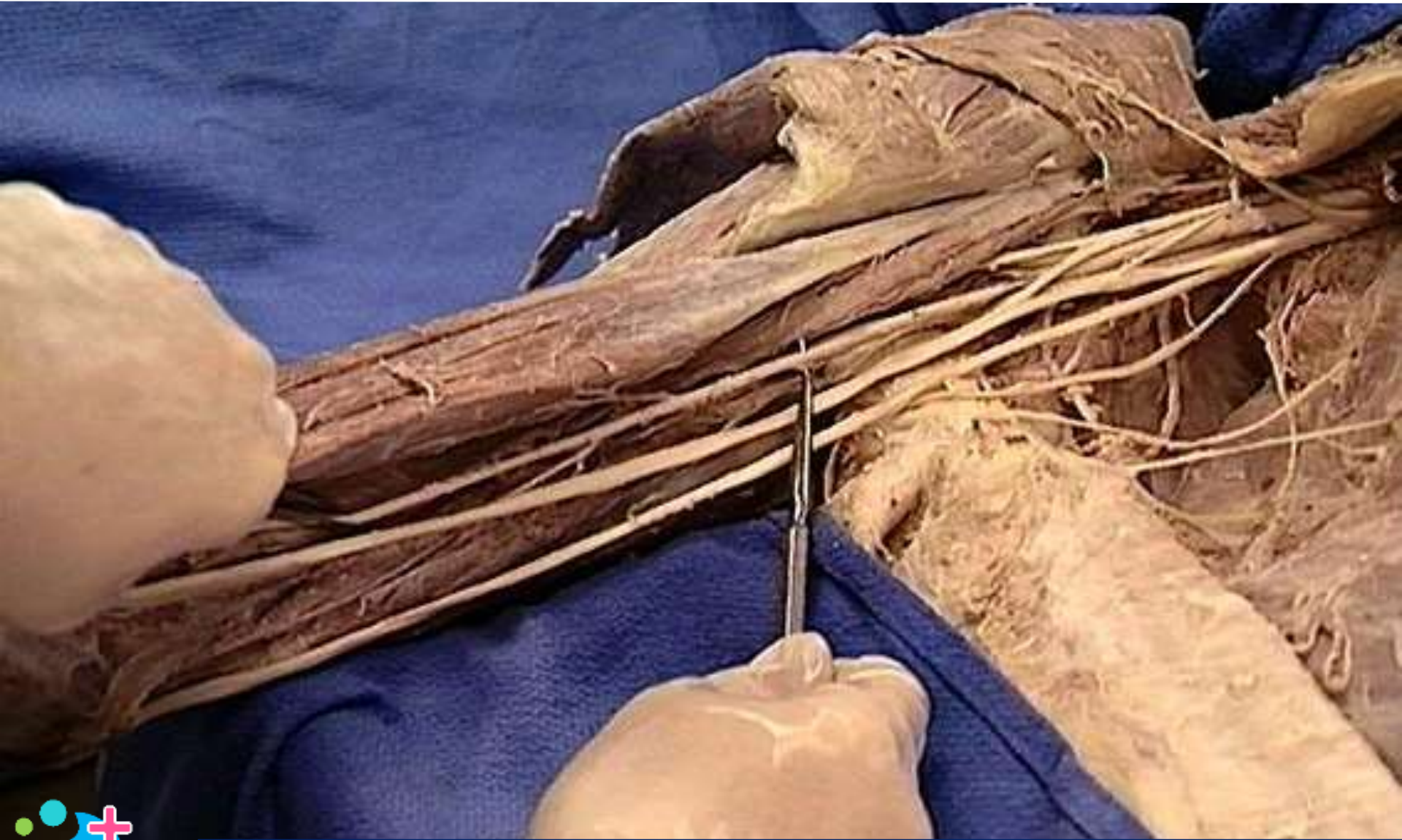
Deep palmer arch



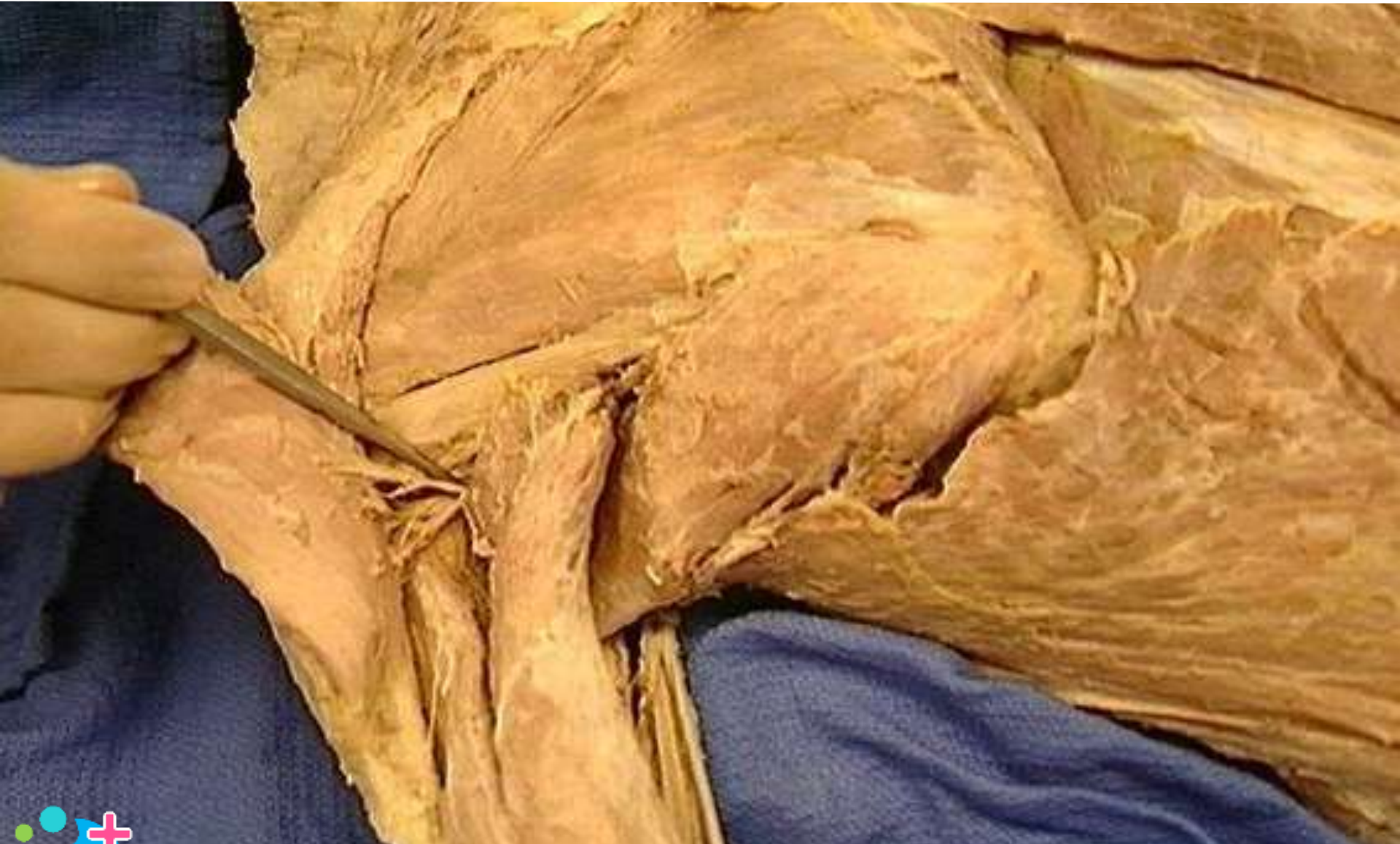Suprascapular artery



Brachial artery



Posterior circumflex humoral artery

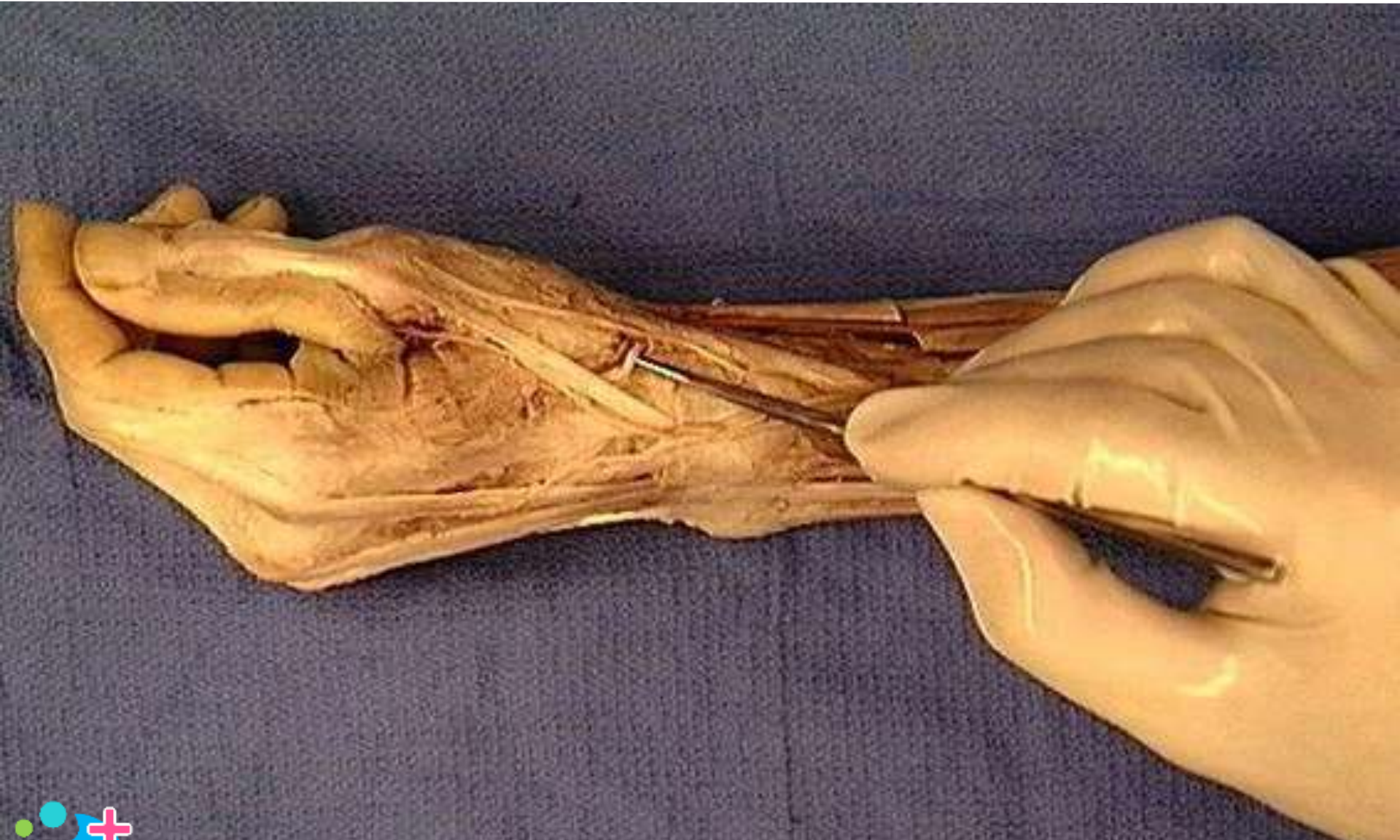

Pronator quadratus

Anterior aspect of forearm and wrist



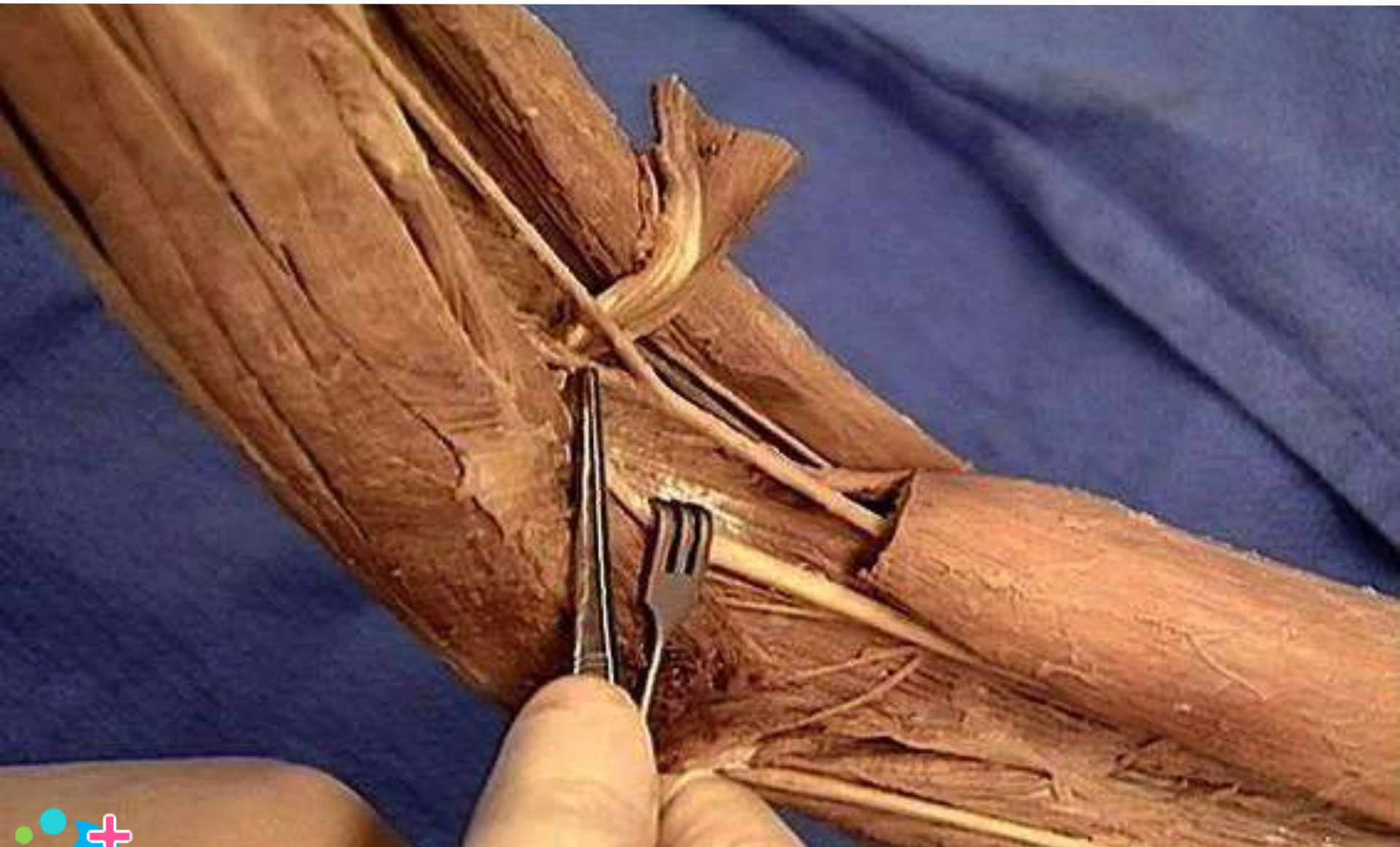
Radial artery



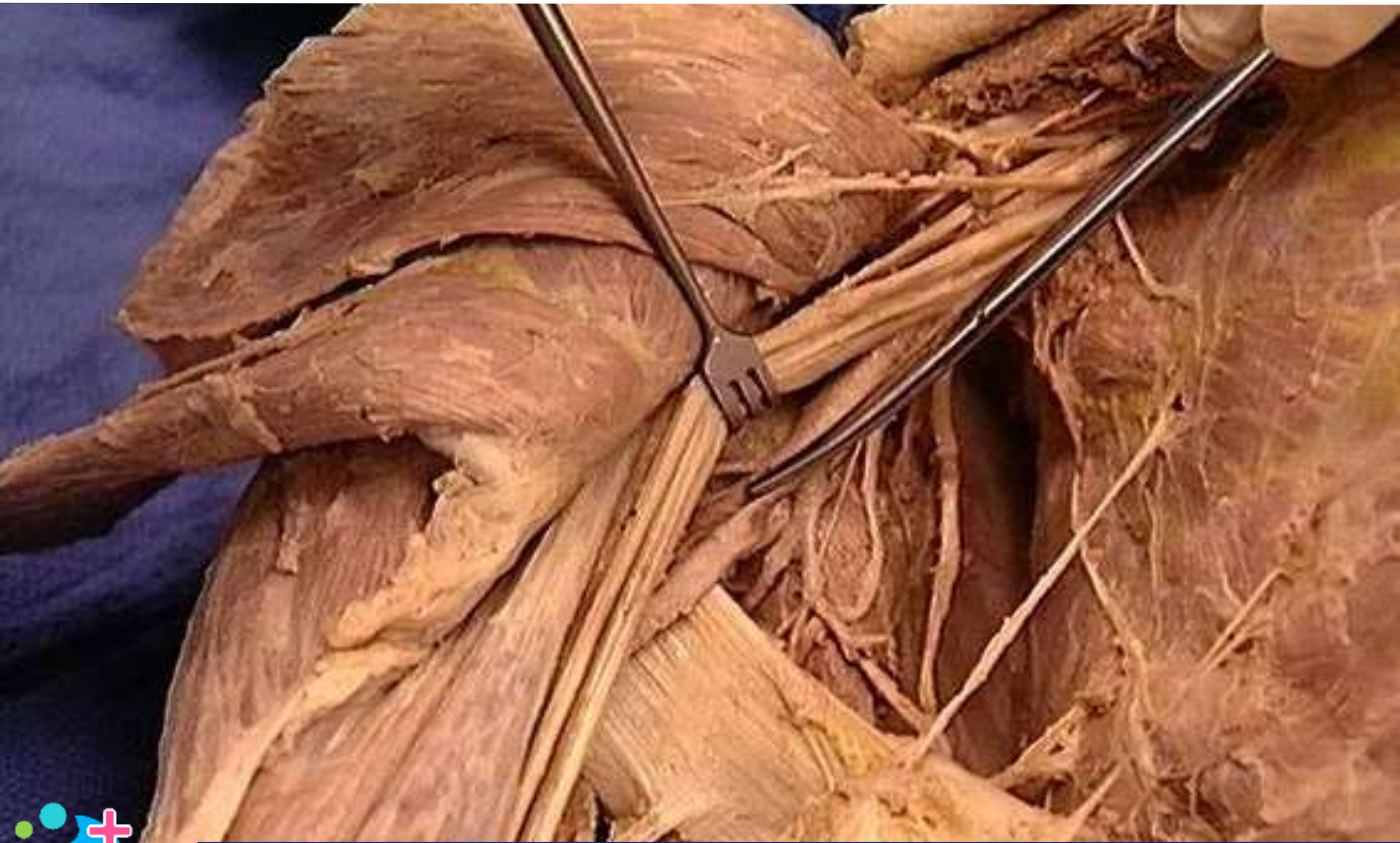Posterior ulnar recurrent artery



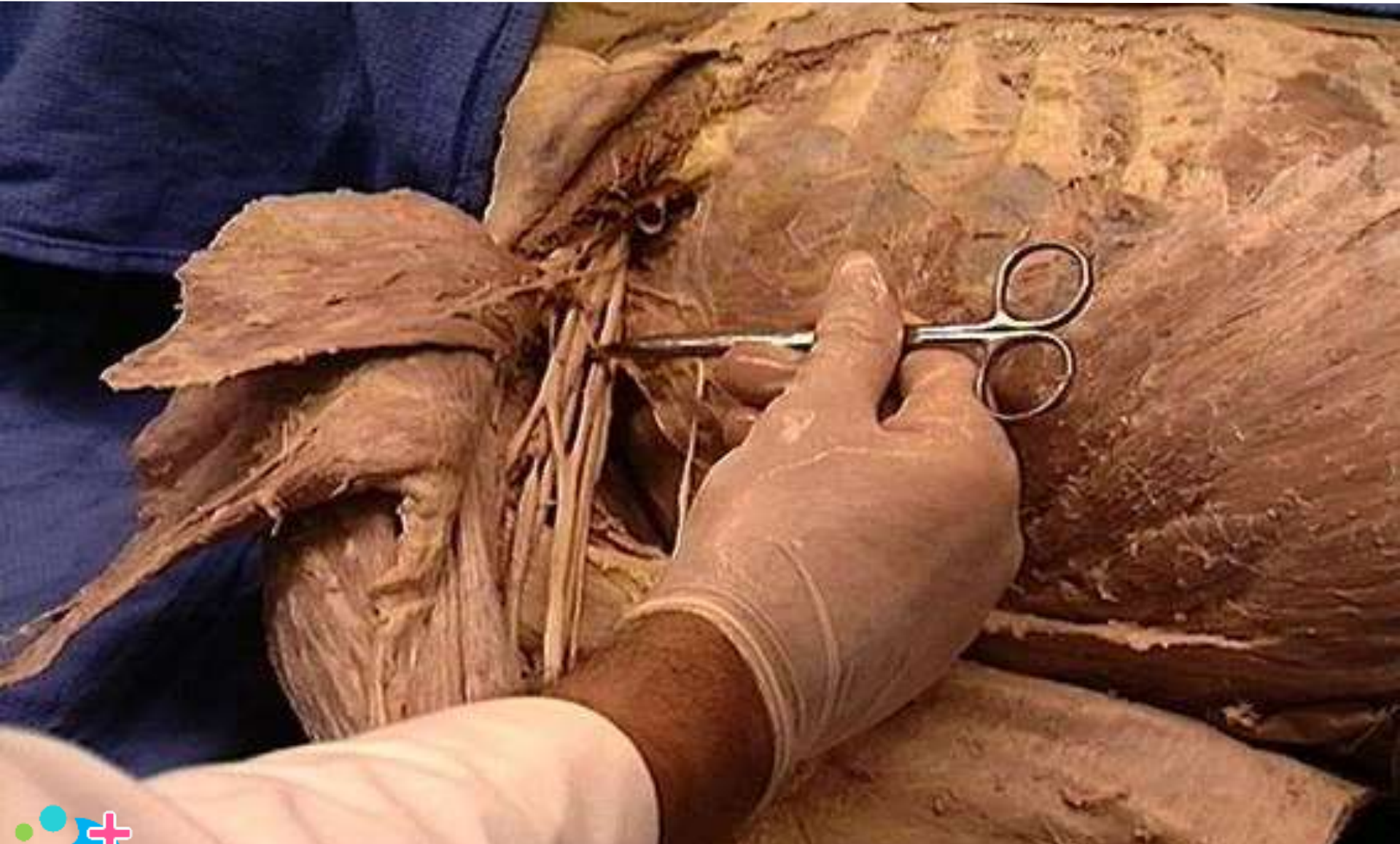
Ulnar artery



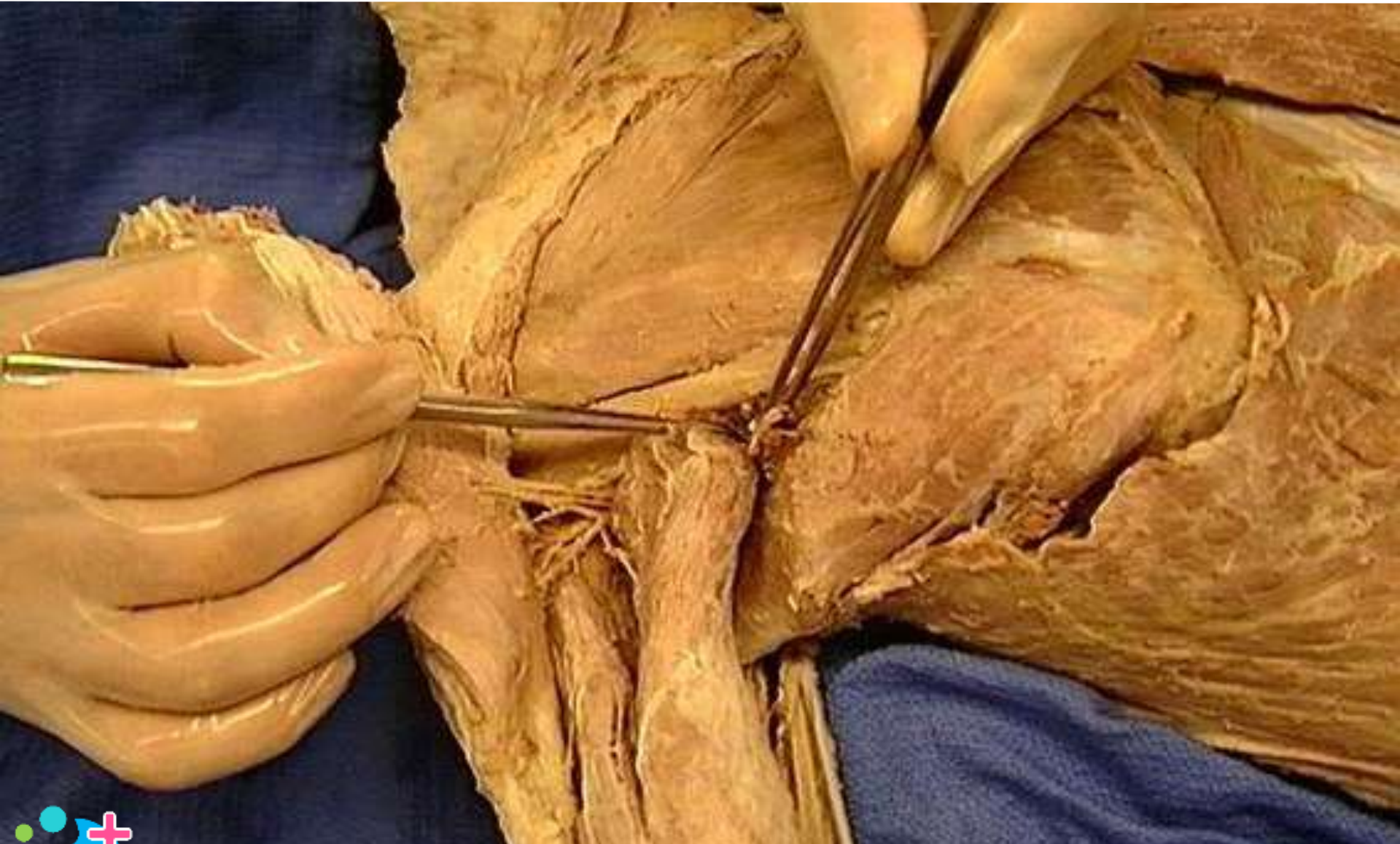
Anterior circumflex humeral artery



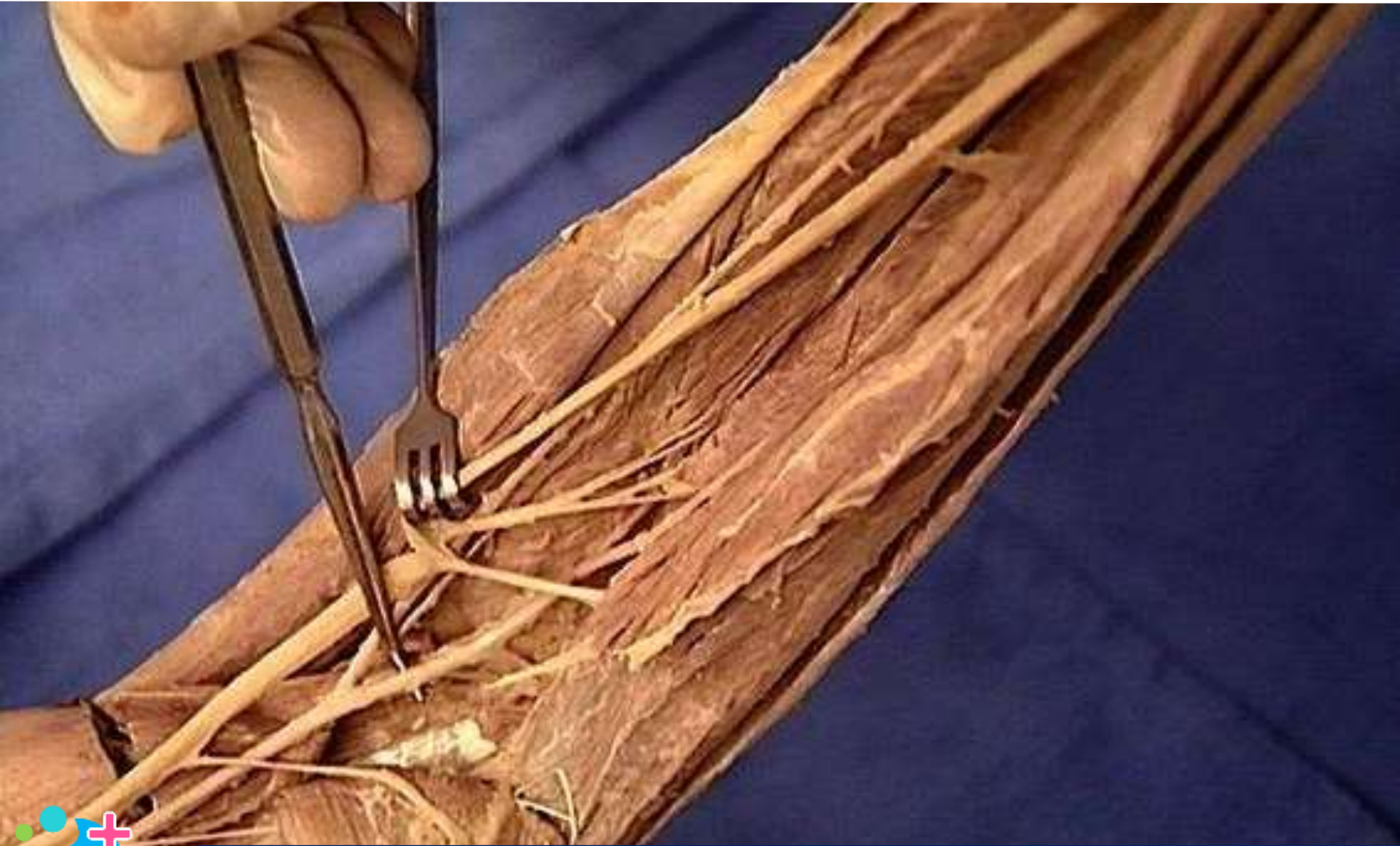Axillary artery : second part



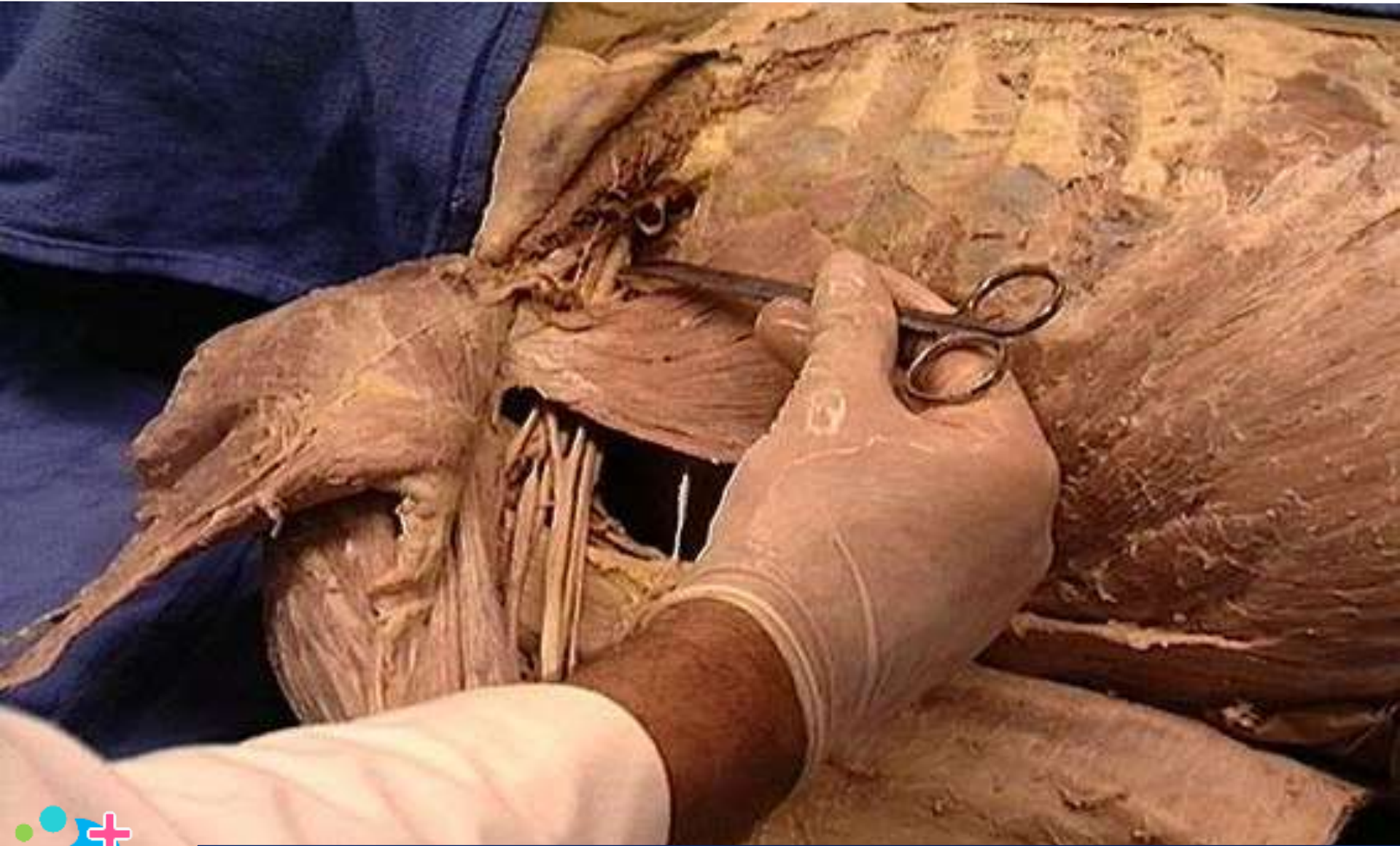Circumflex scapular artery



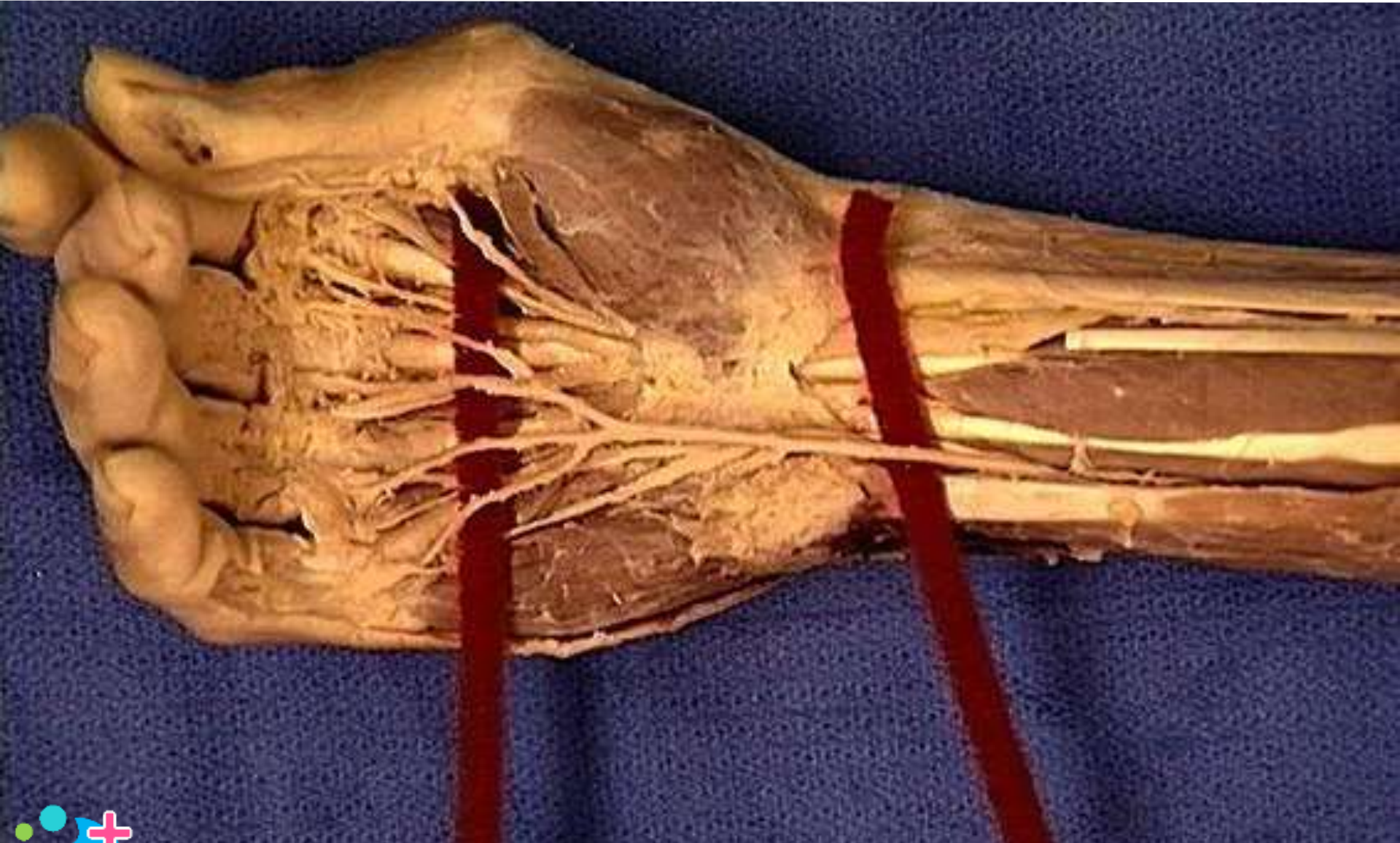
Ulnar artery



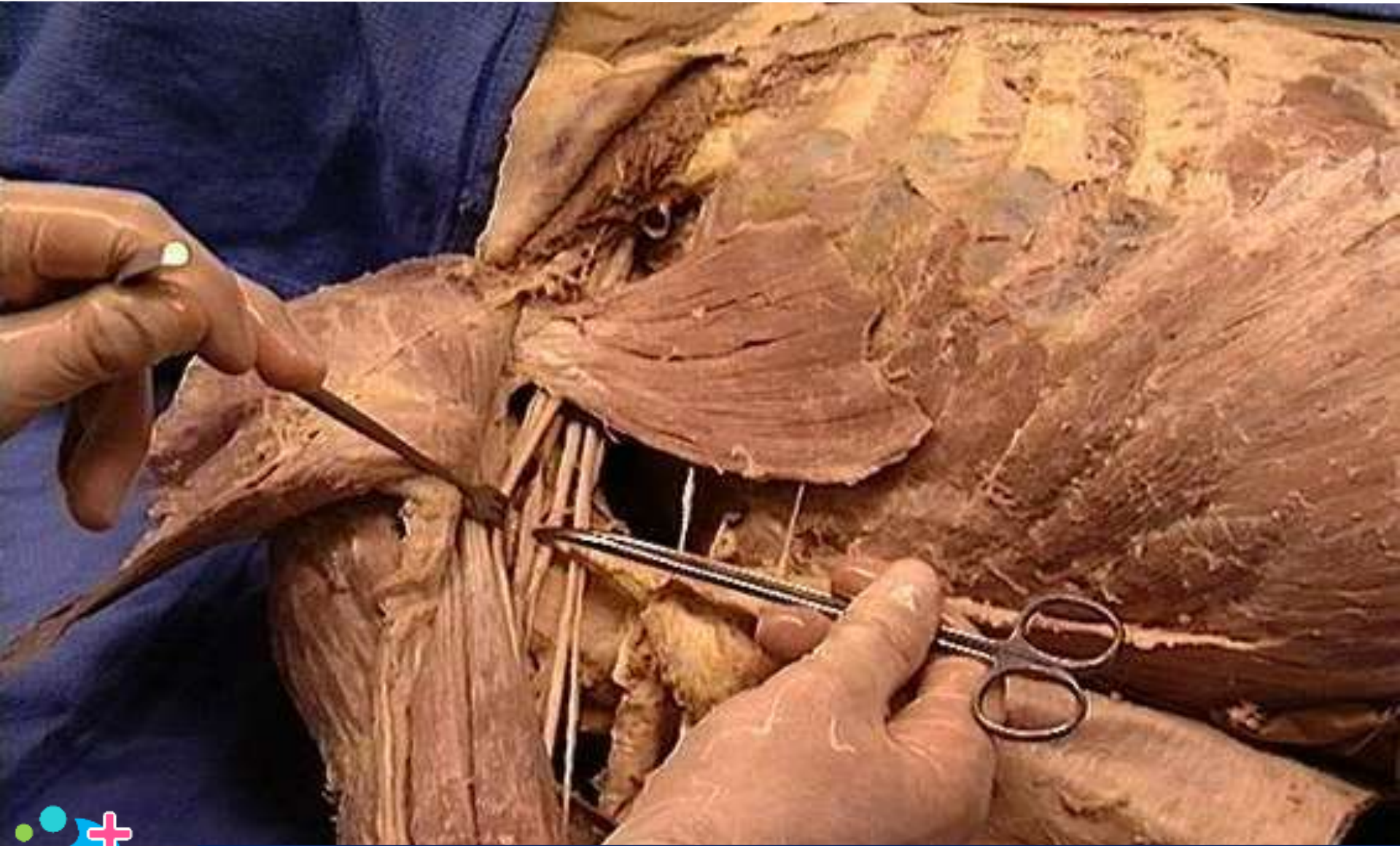
Axillary artery : first part



Ulnar artery



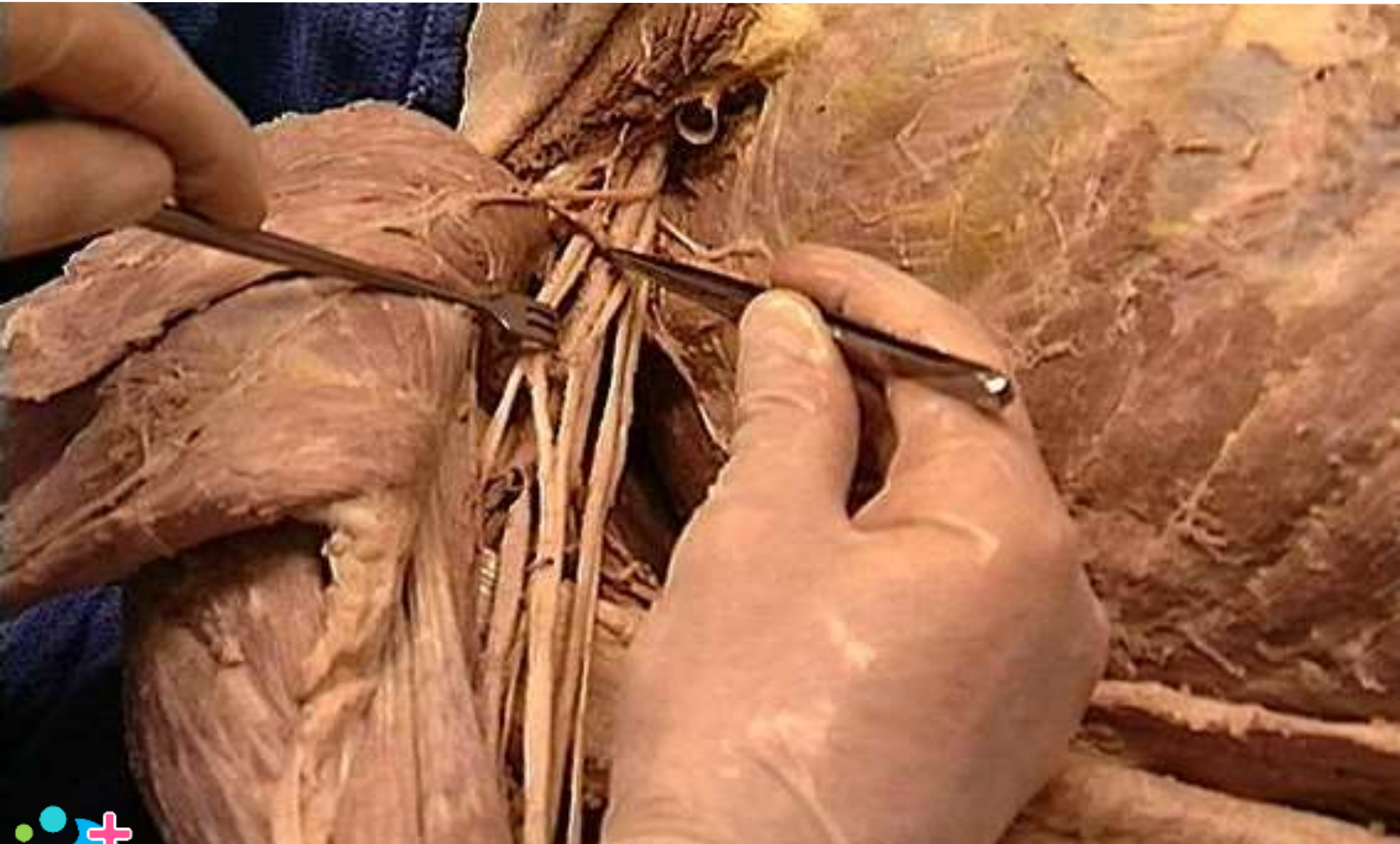Axillary artery: third part



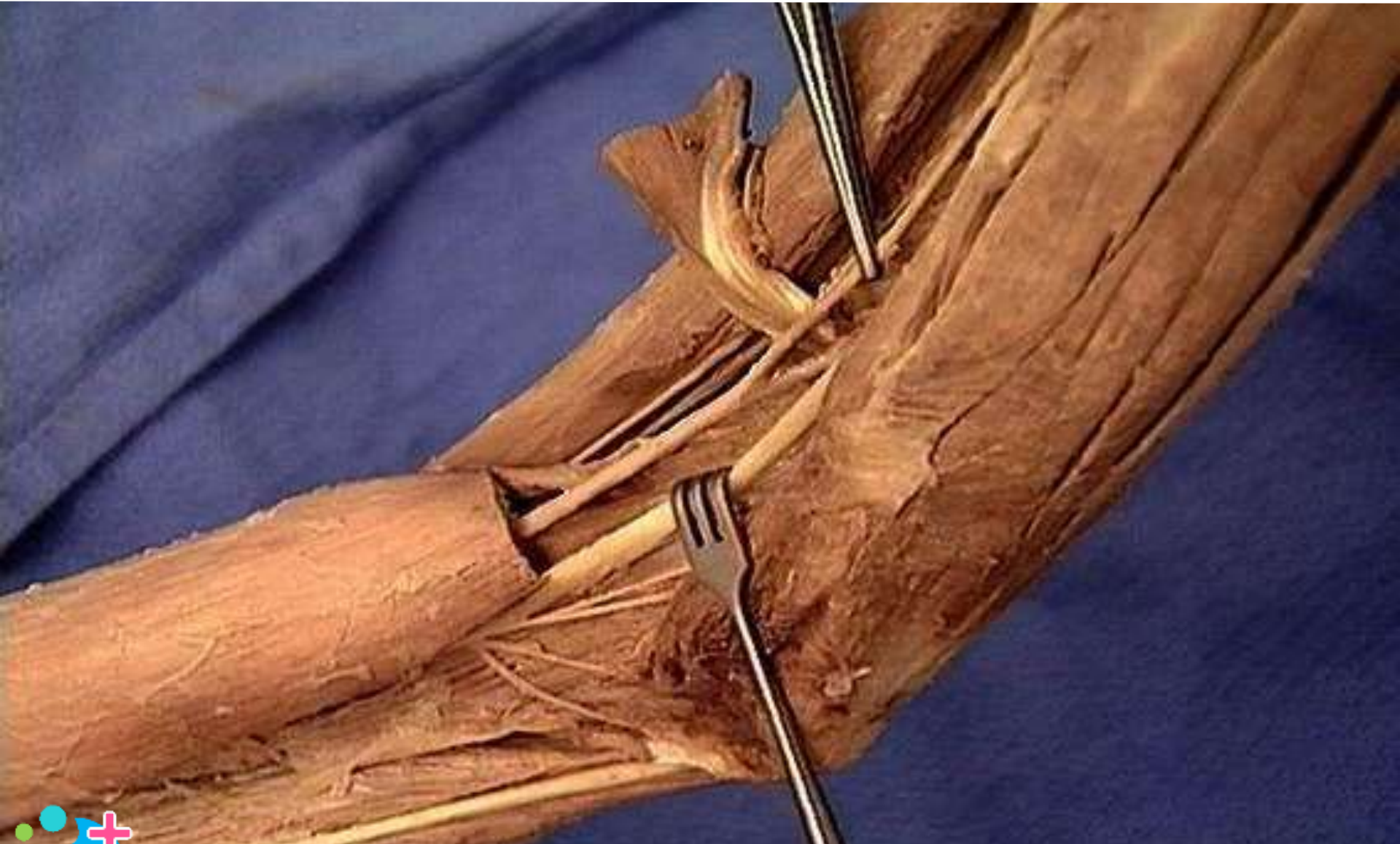Thoracoacromial trunk (artery): pectoral branch



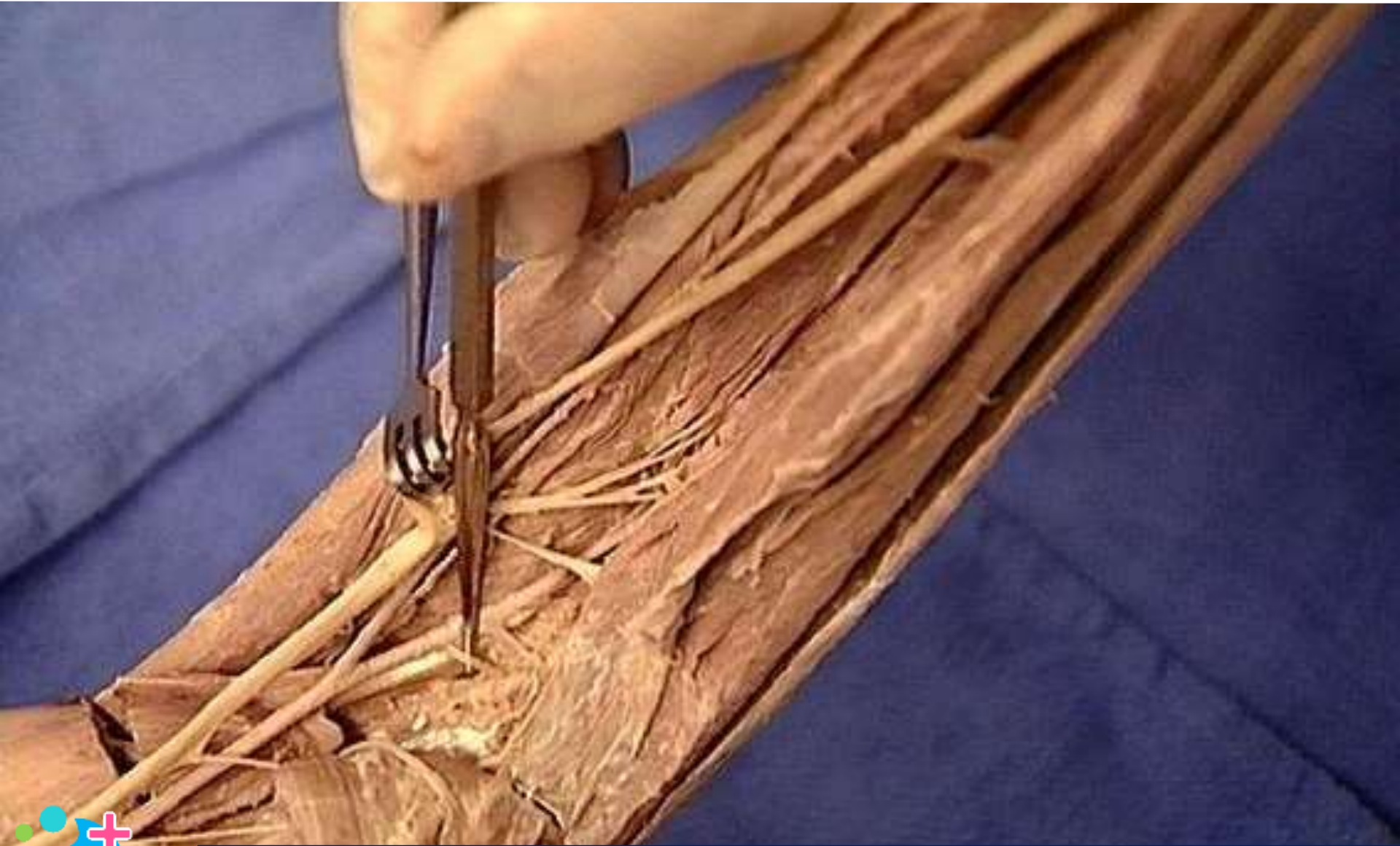
Thoracoacromial trunk (artery)



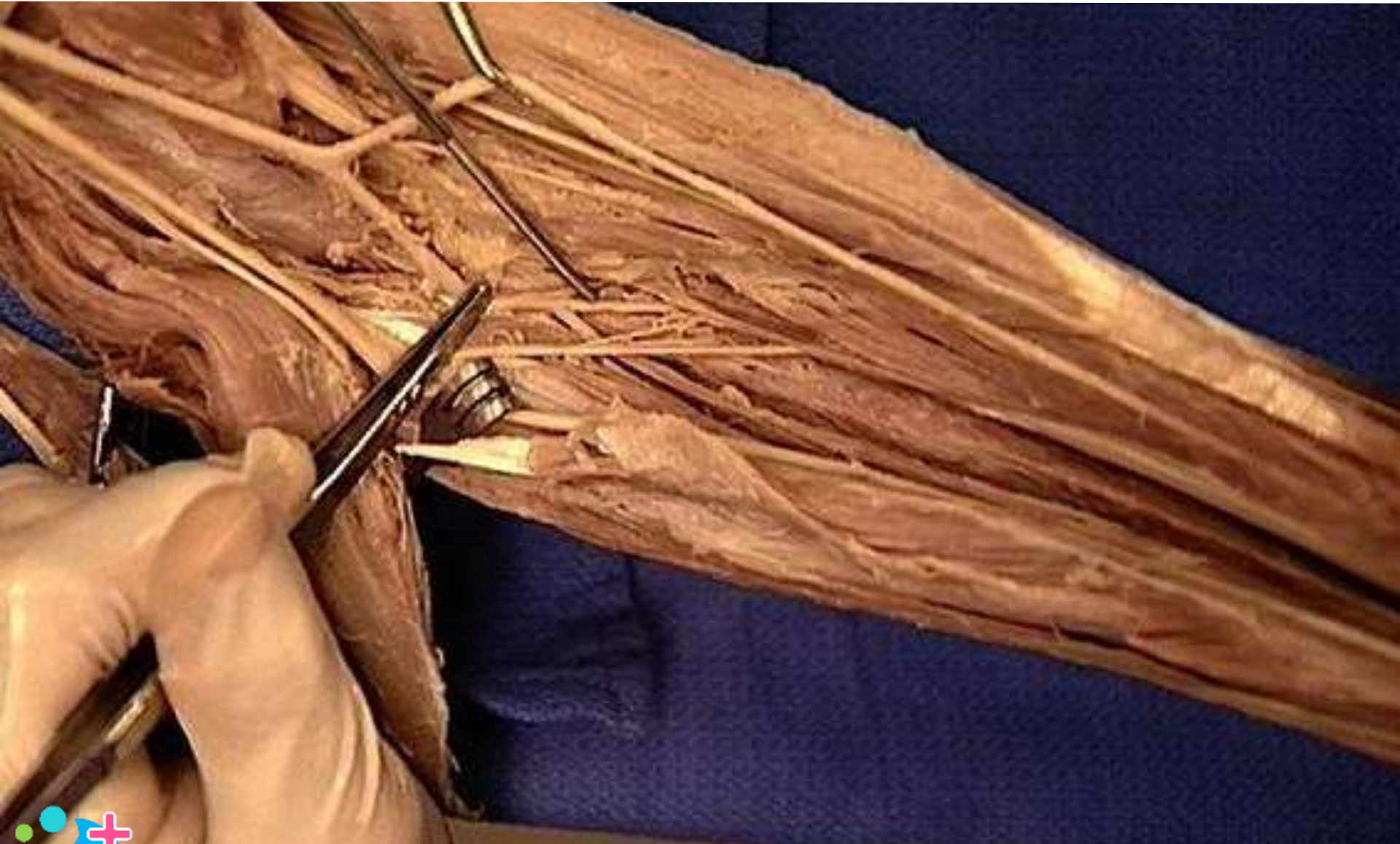Radial artery



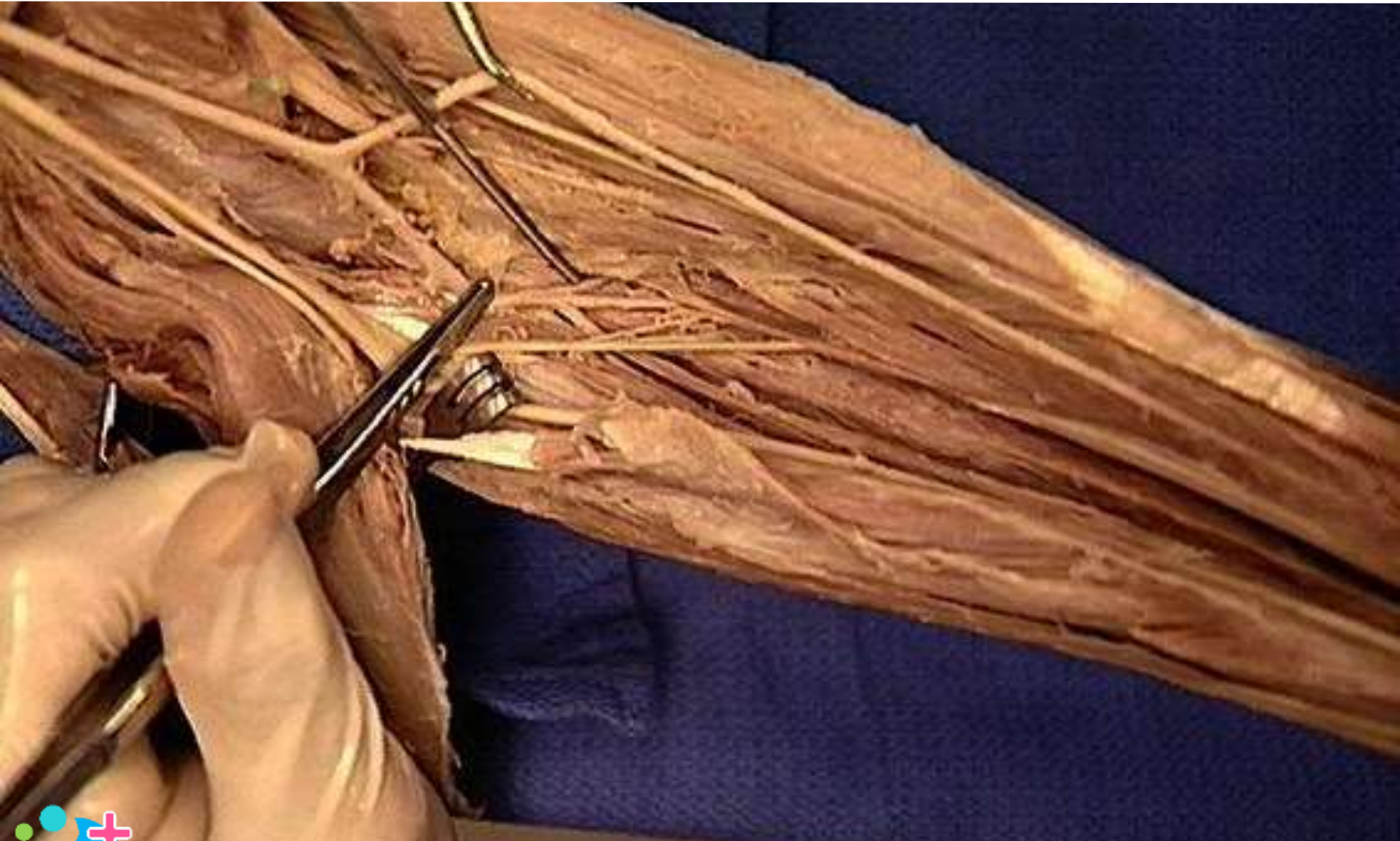
Anterior ulnar recurrent artery



Anterior interosseous artery



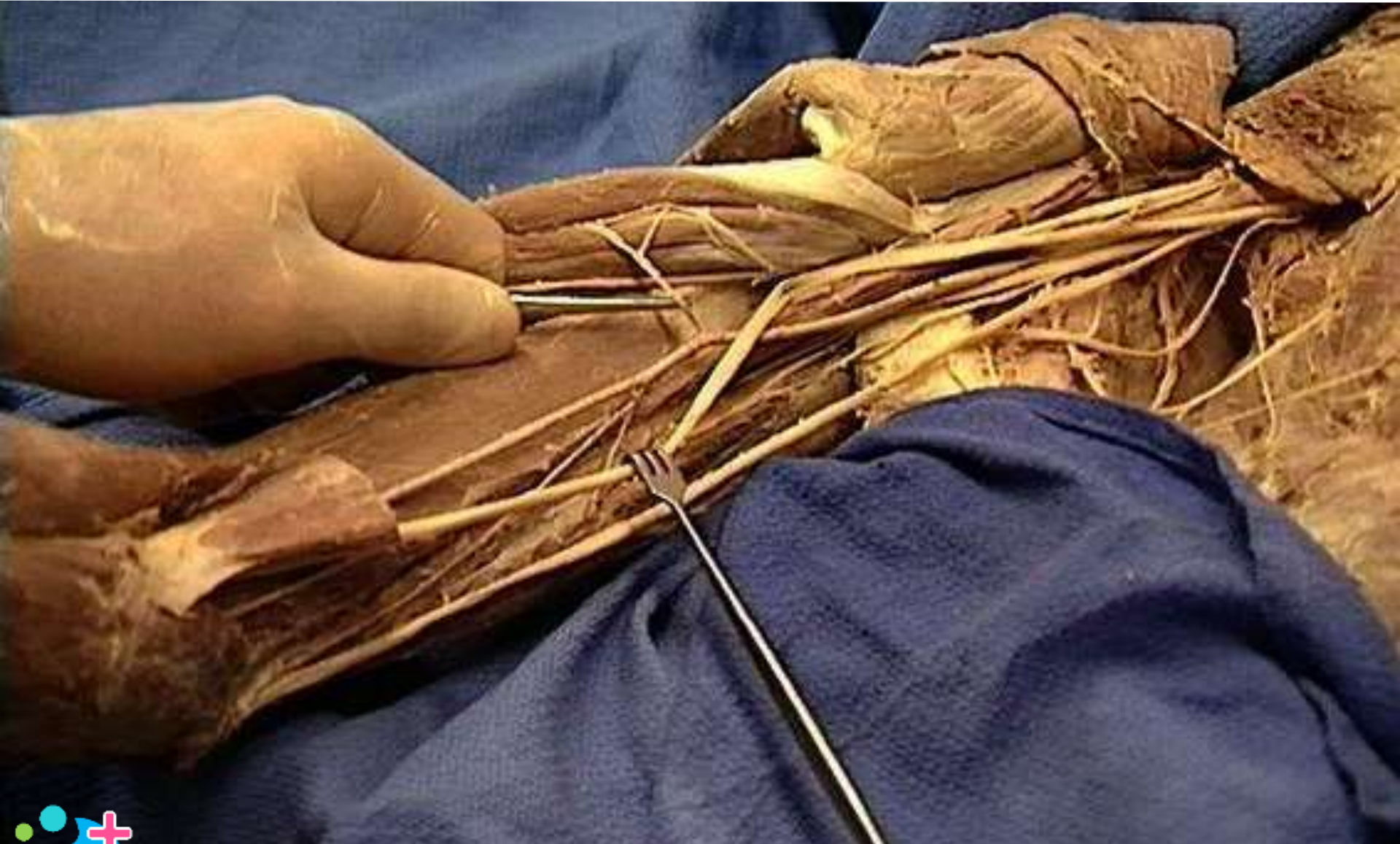
Posterior interosseous artery



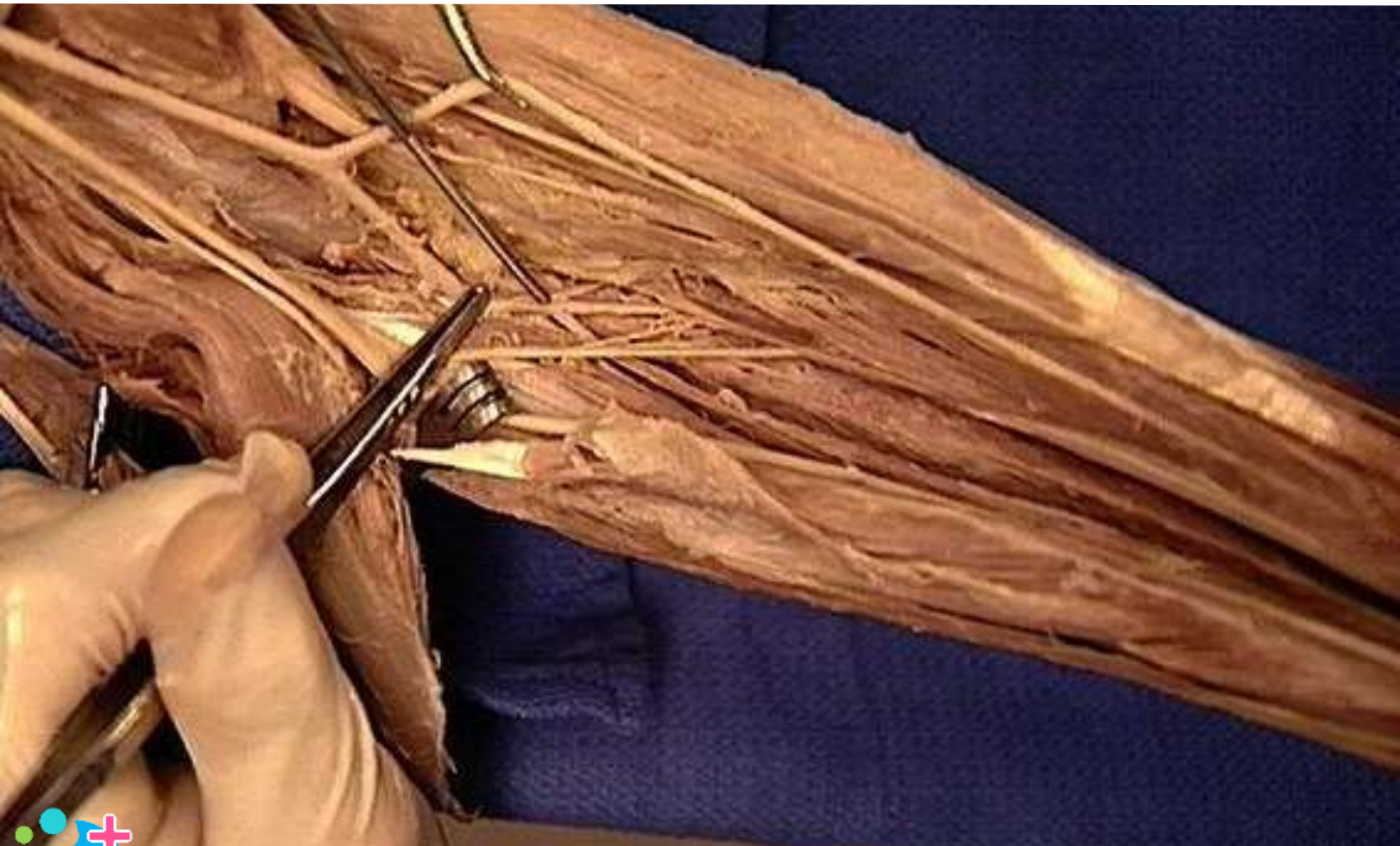Thoracodorsal artery



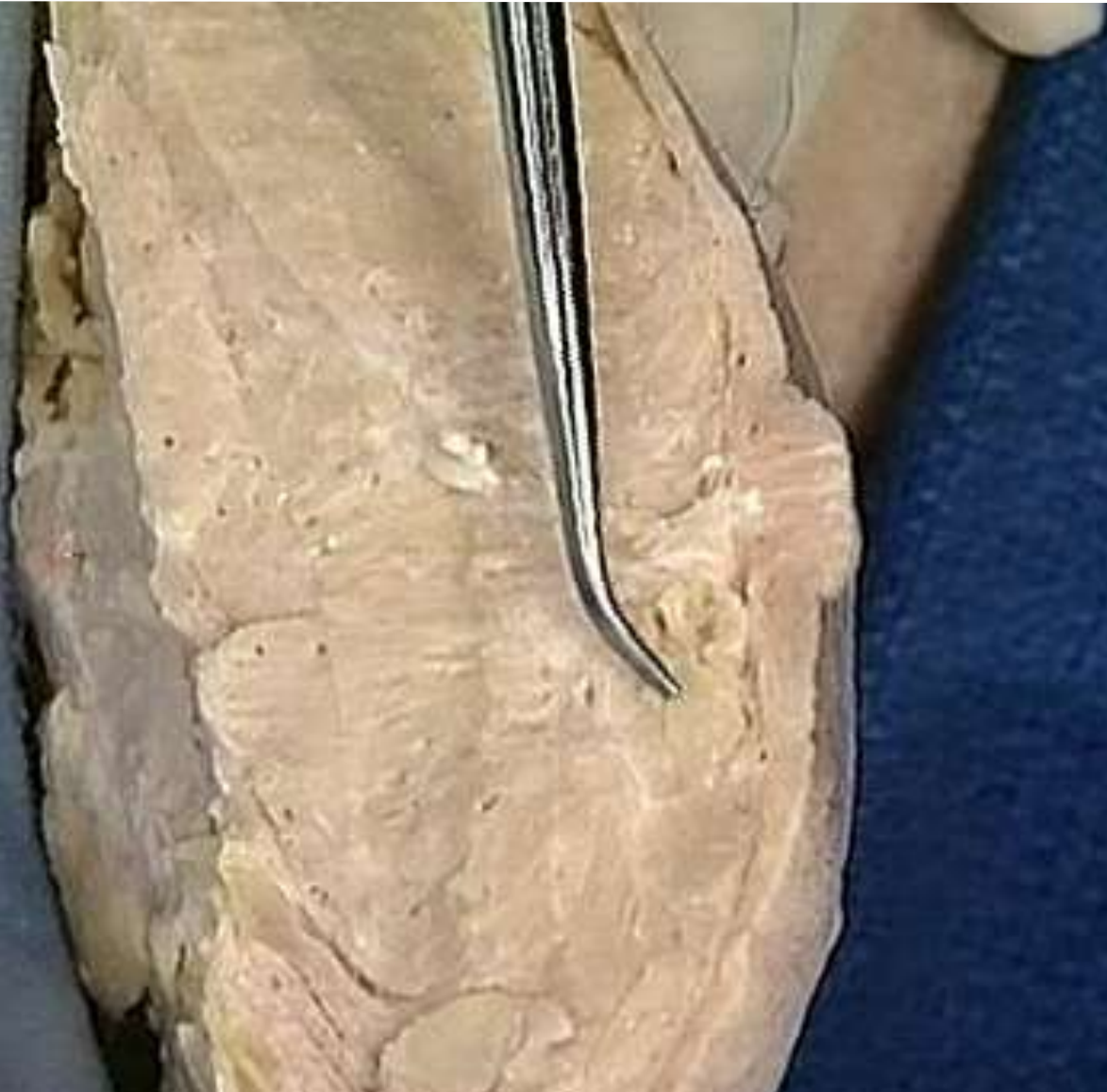Brachial artery : muscular branches



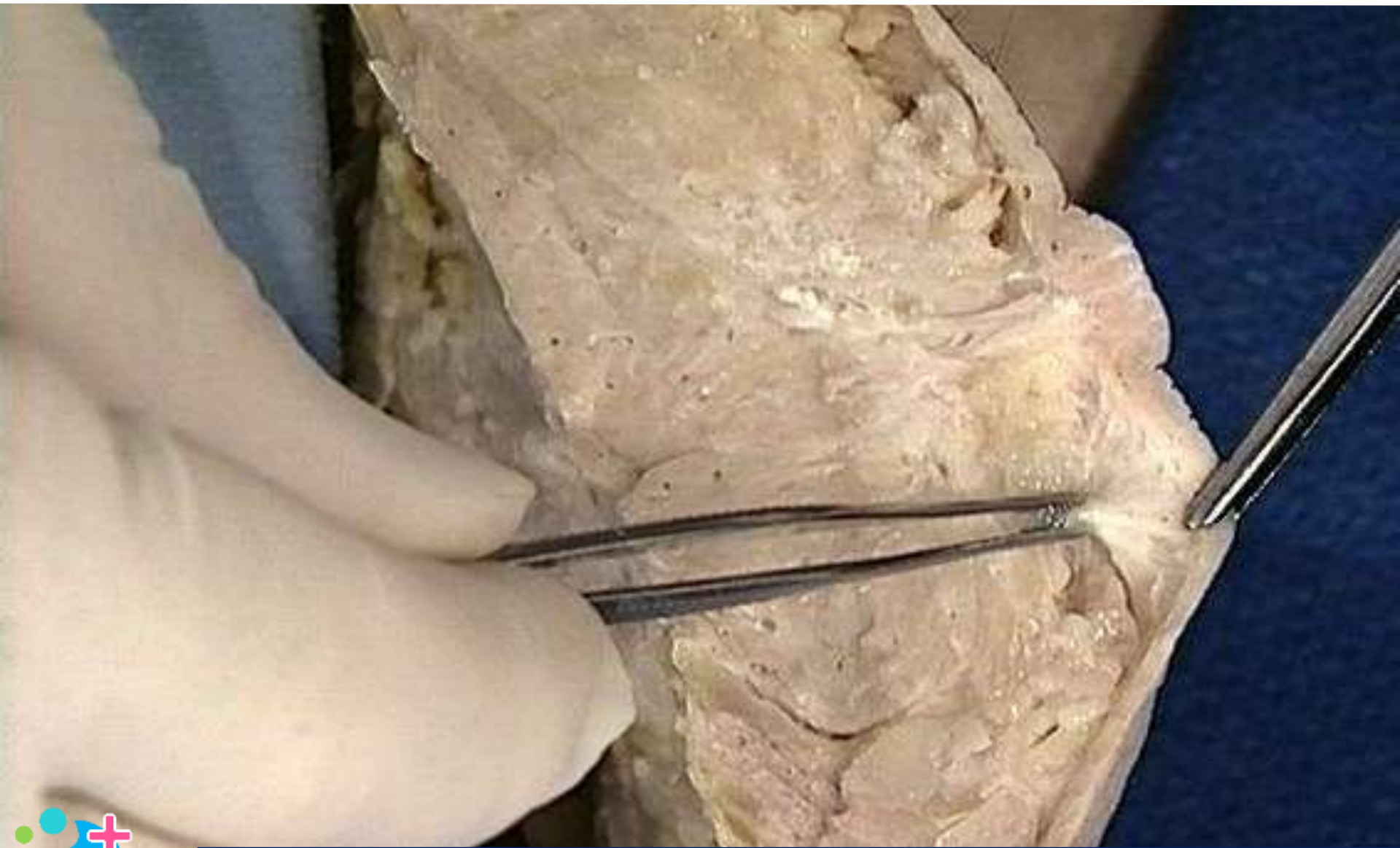
Common interosseous artery



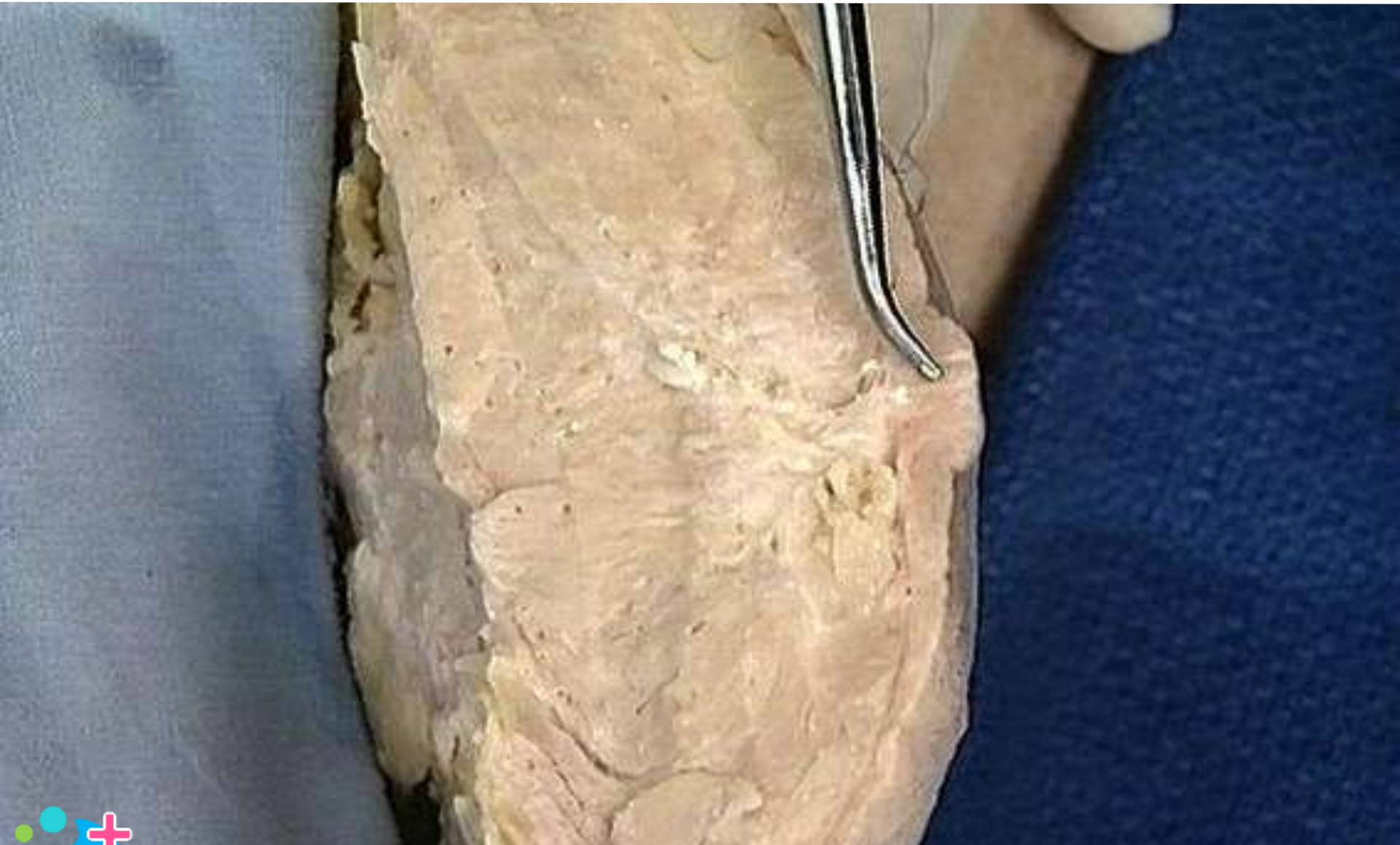Breast : glandular tissue



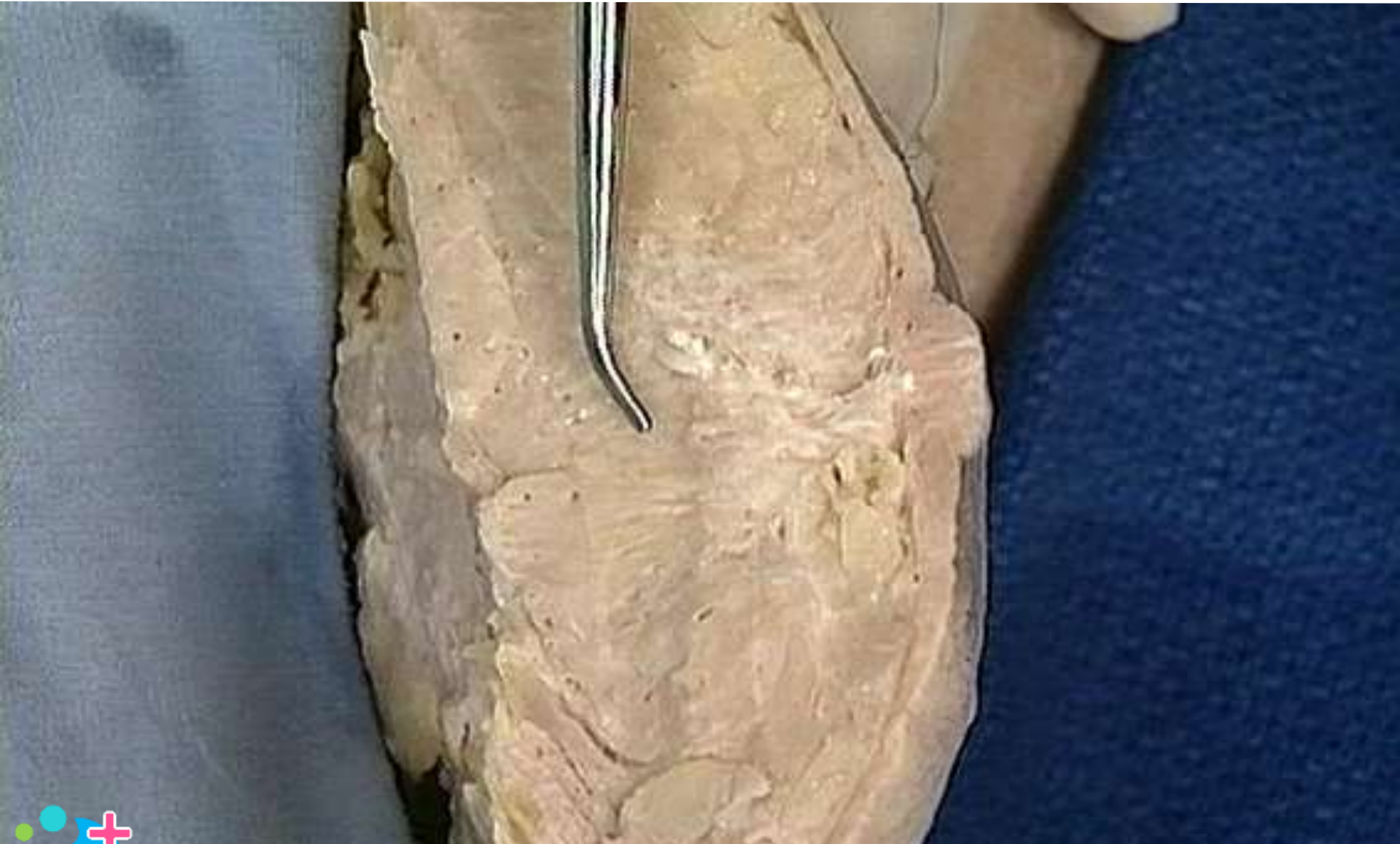Breast : suspensory ligament



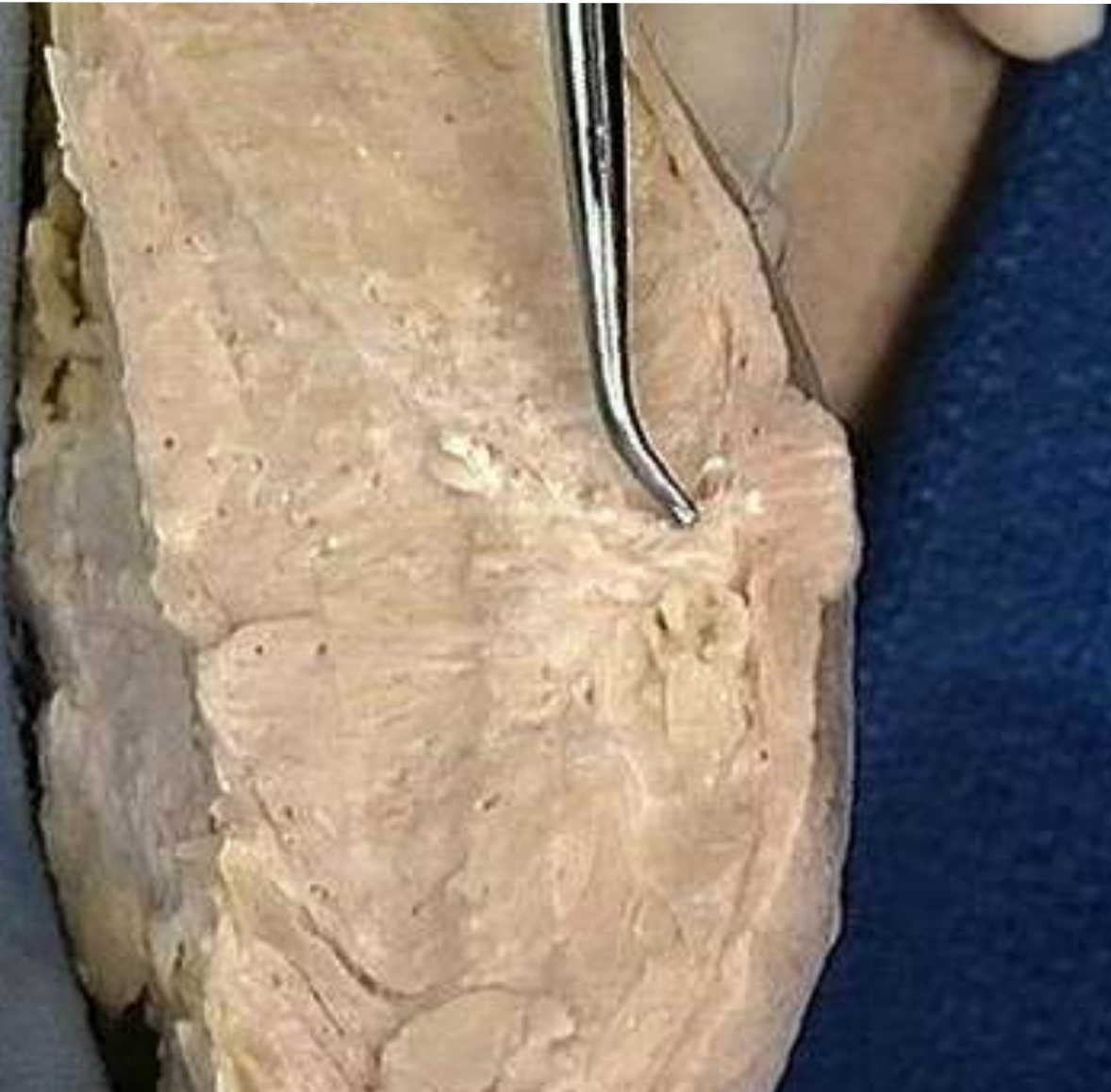Lactiferous duct of breast



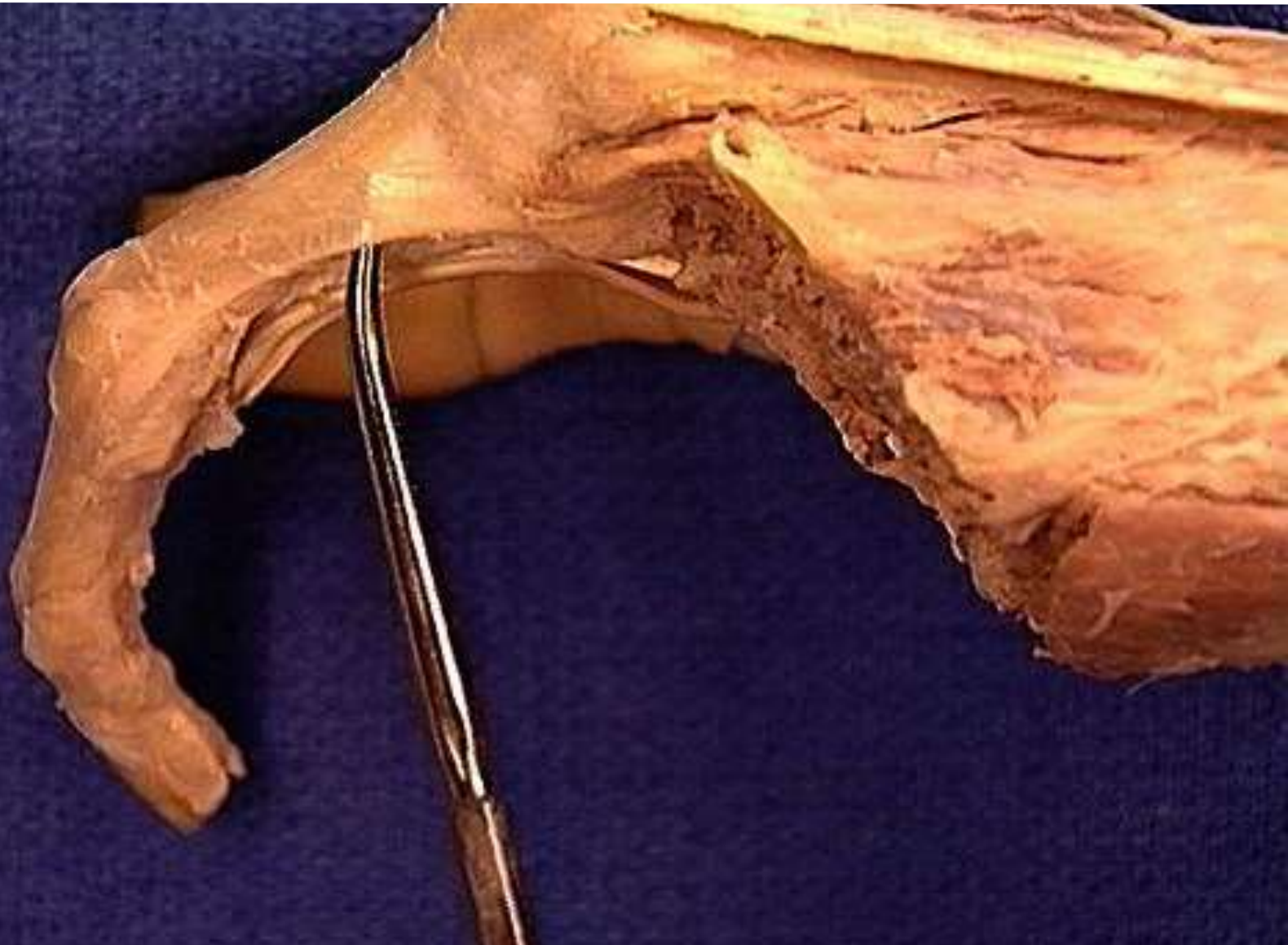Breast: glandular tissue



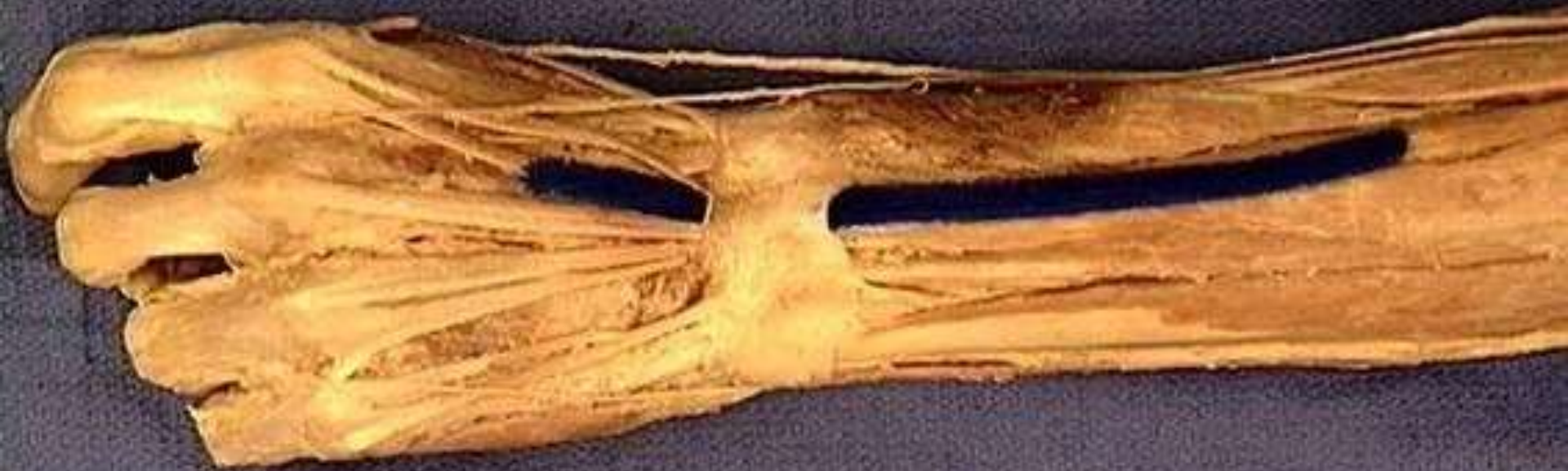Lactiferous sinus of breast



Extensor expansion of finger



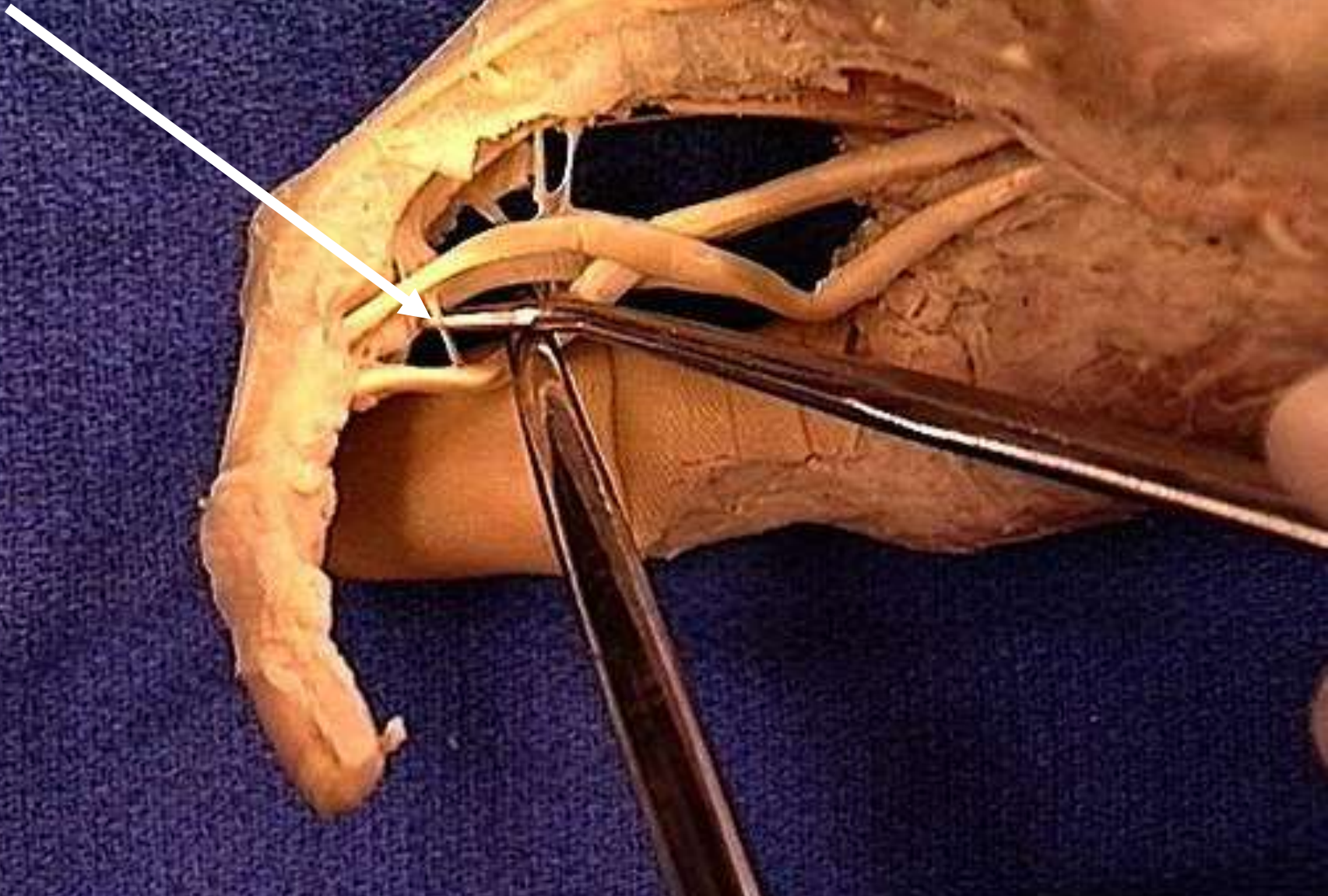
Extensor retinaculum



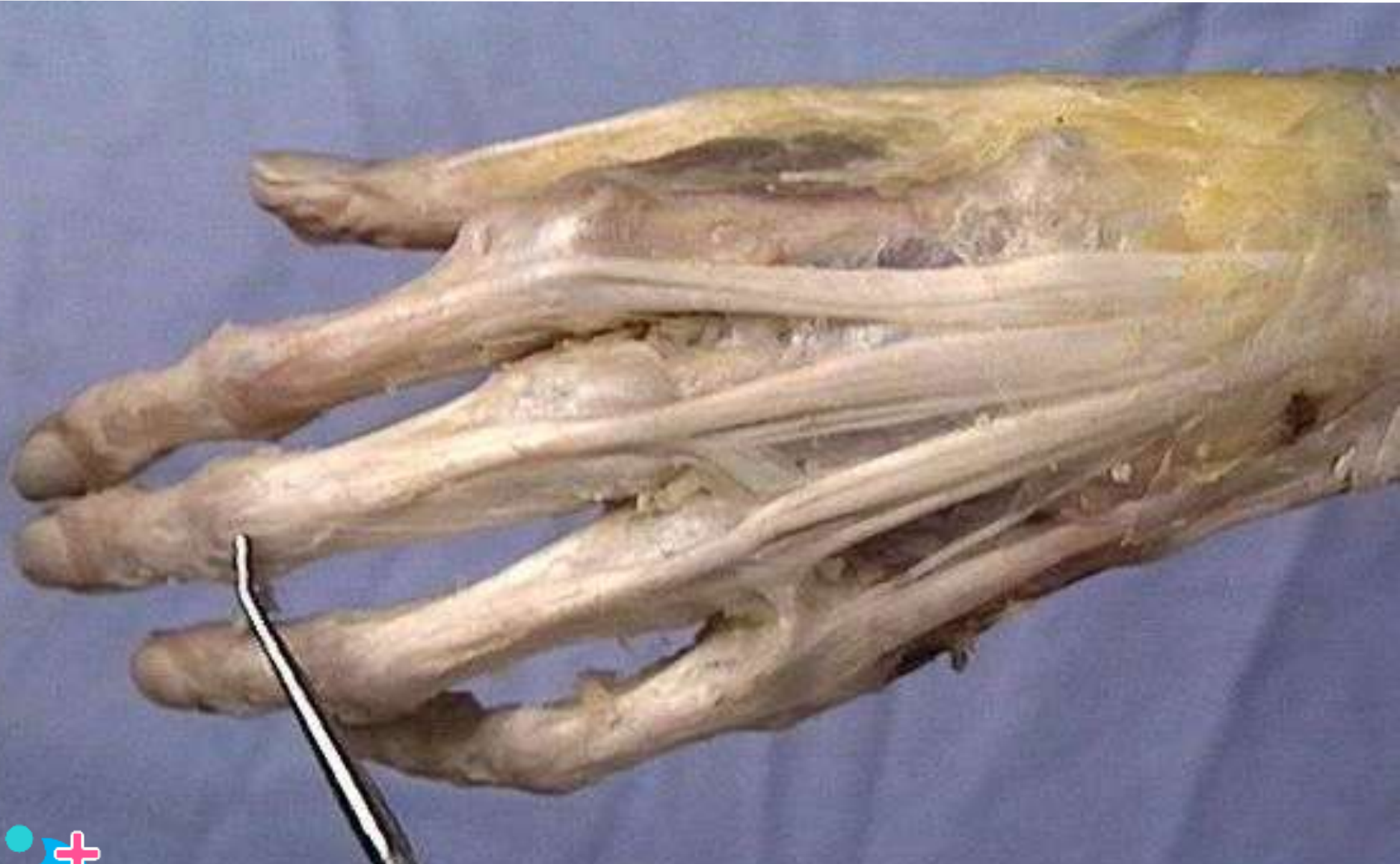Flexor retinaculum



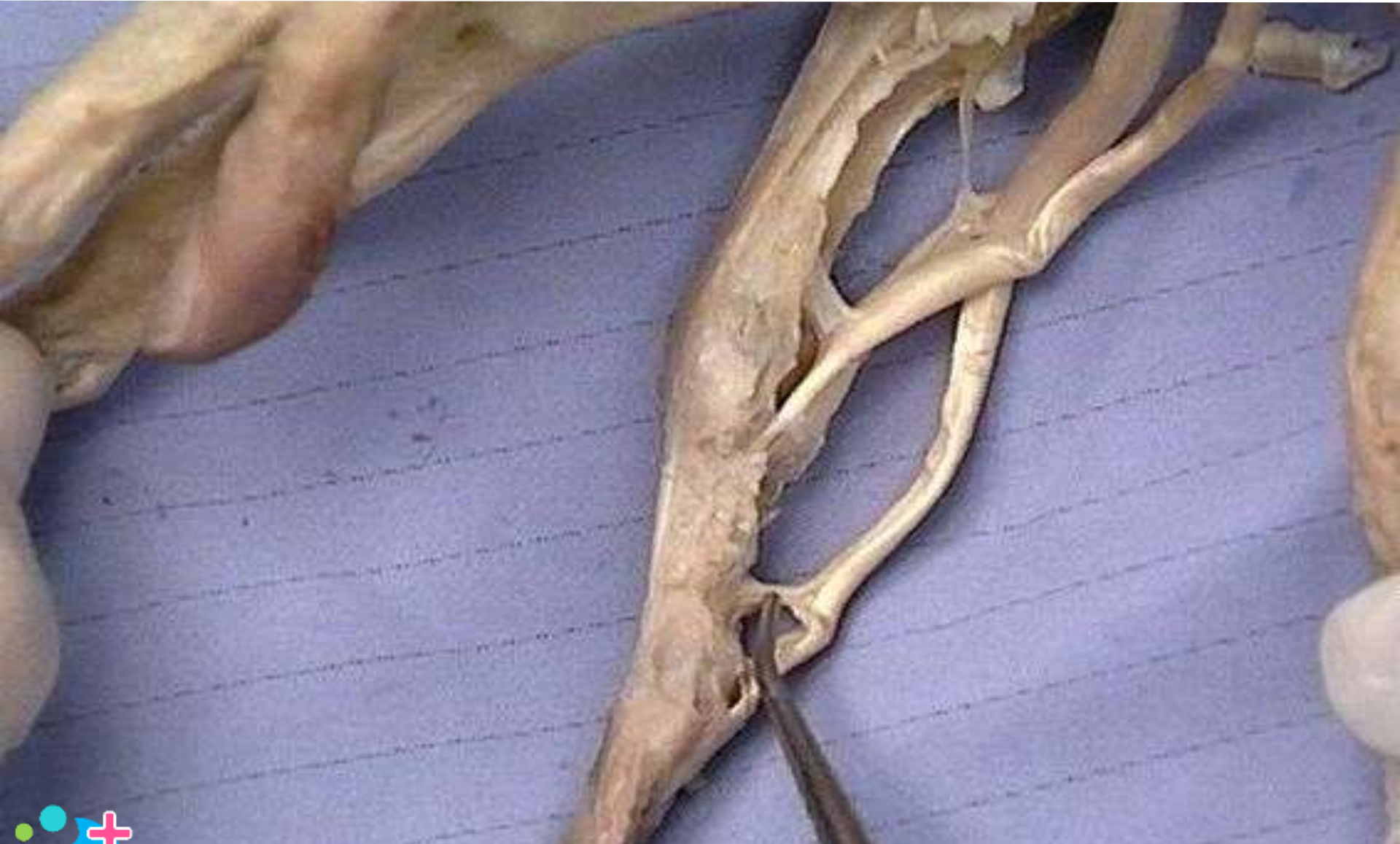Vinicula longa



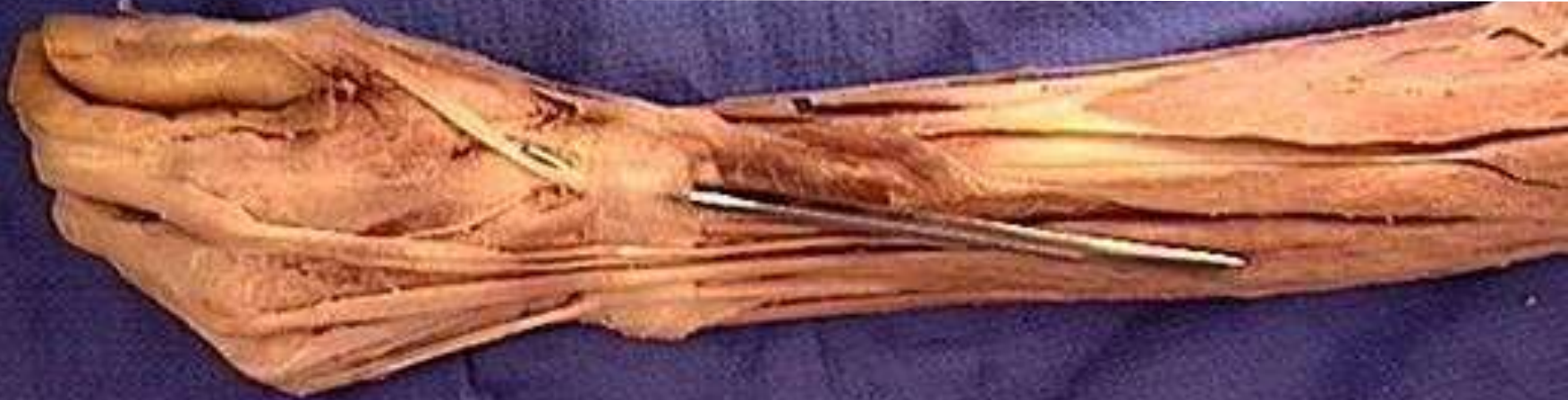Extensor expansion of finger



Vinicula brevia

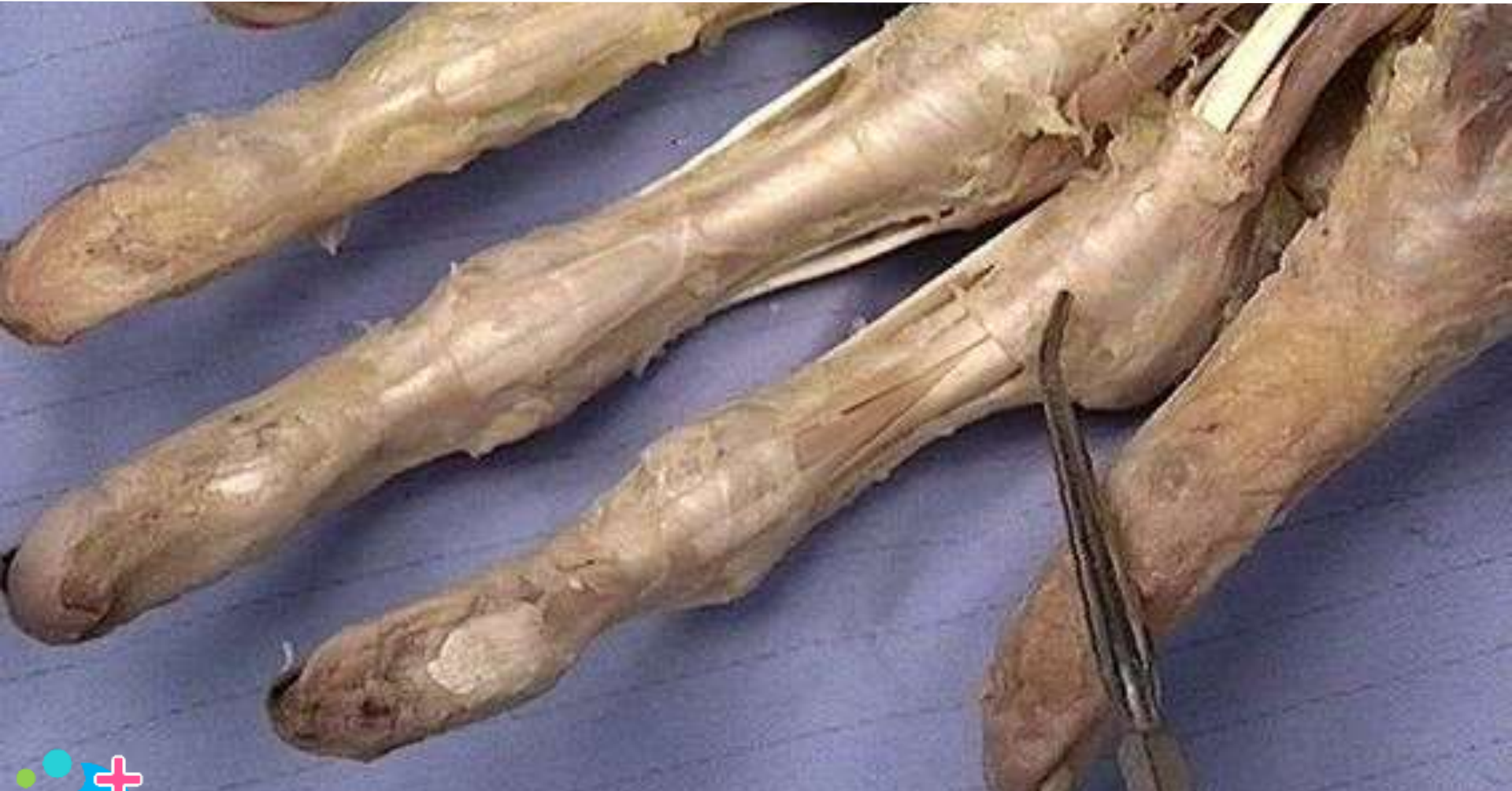

Osteofibrous compartment: 3rd extensor of wrist

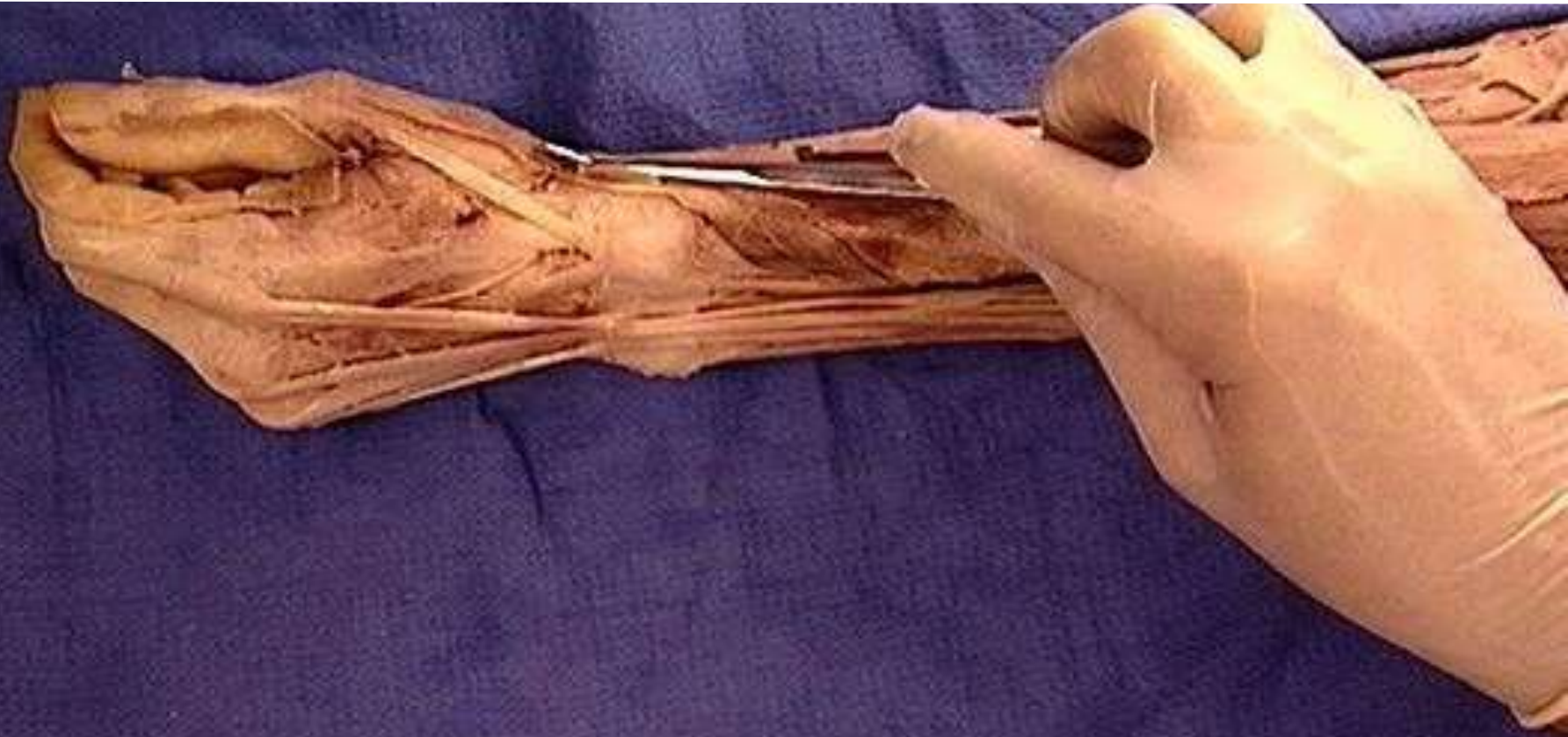


Hint: Opening through which probe passes?

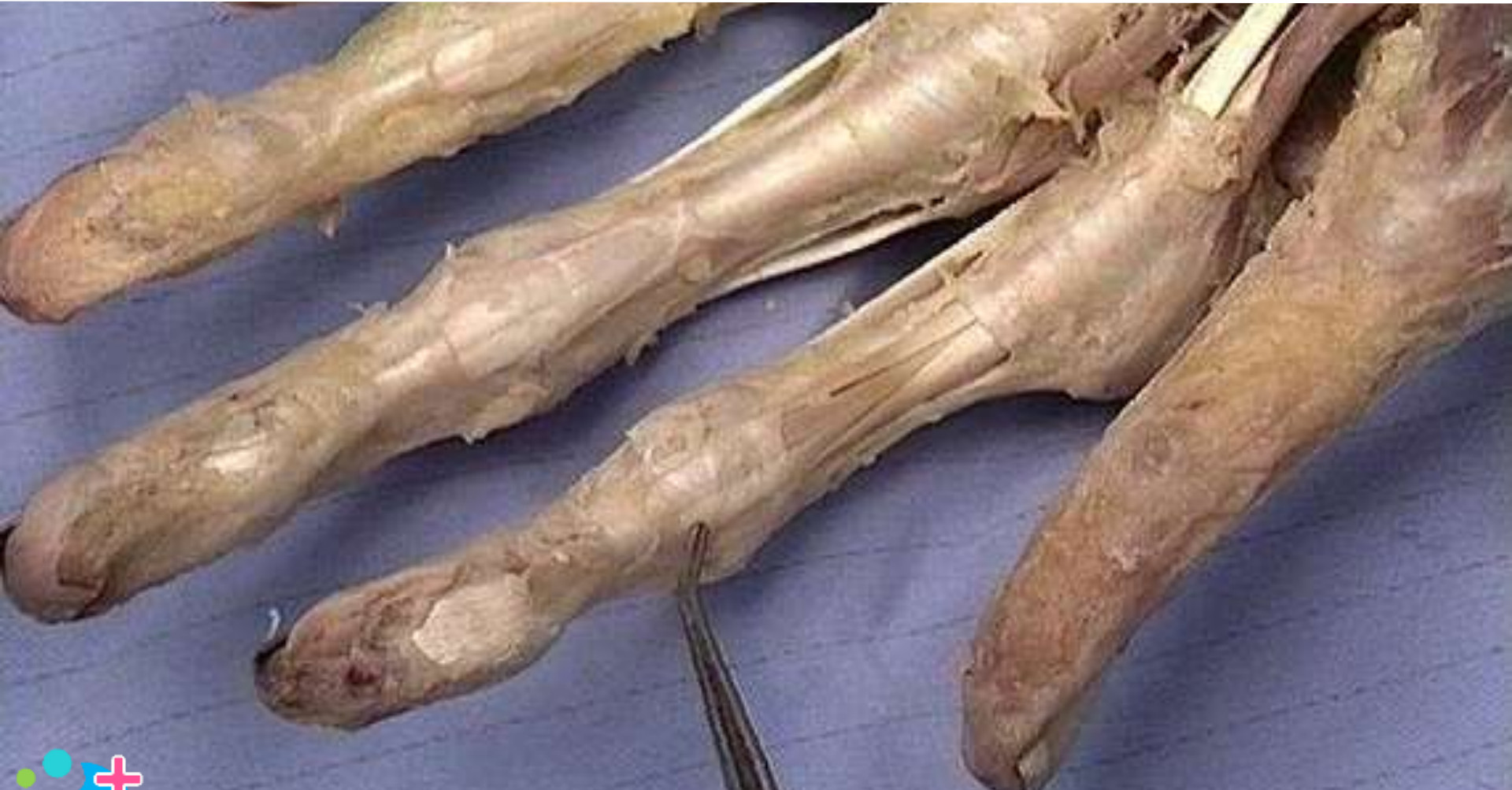Palmar ligament of metacarpophalangeal joint



Osteofibrous compartment: 1st extensor of wrist



Palmar ligament of proximal interphalangeal joint

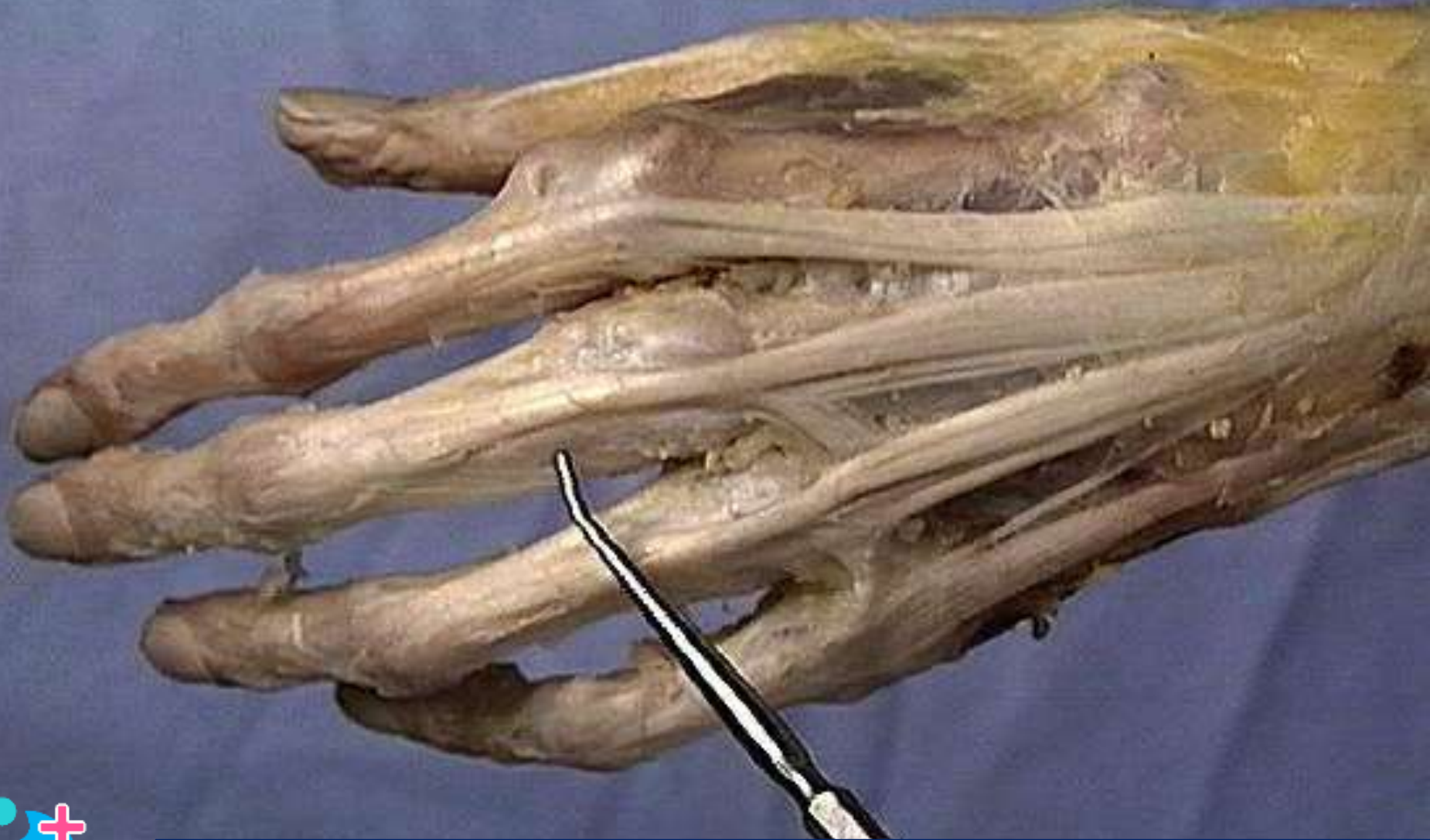


Osteofibrous compartment: 6th extensor of wrist

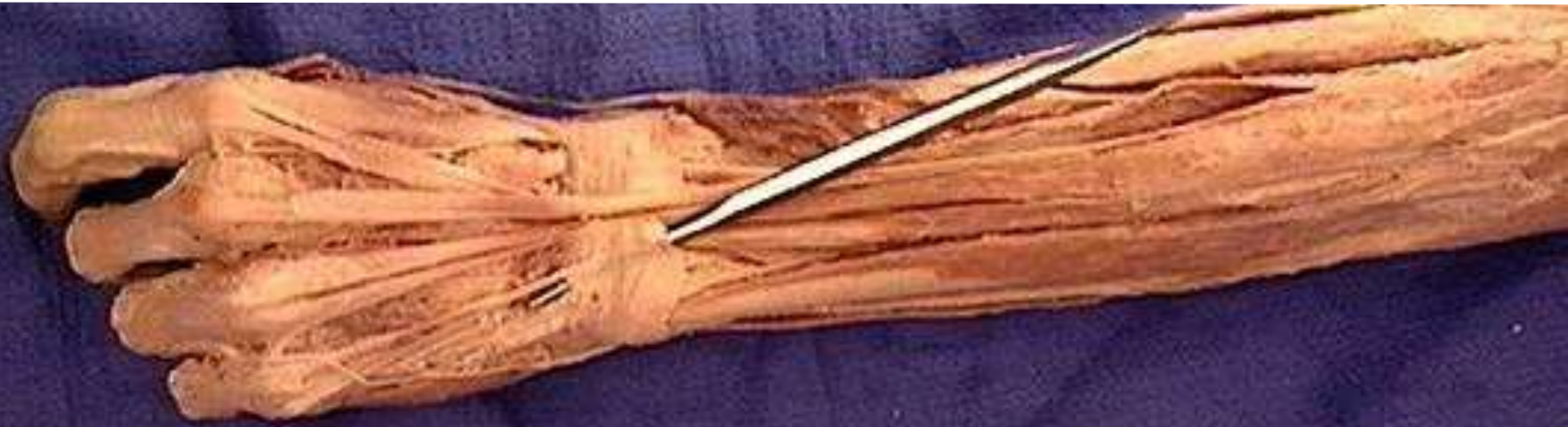

Hint: Opening through which probe passes?

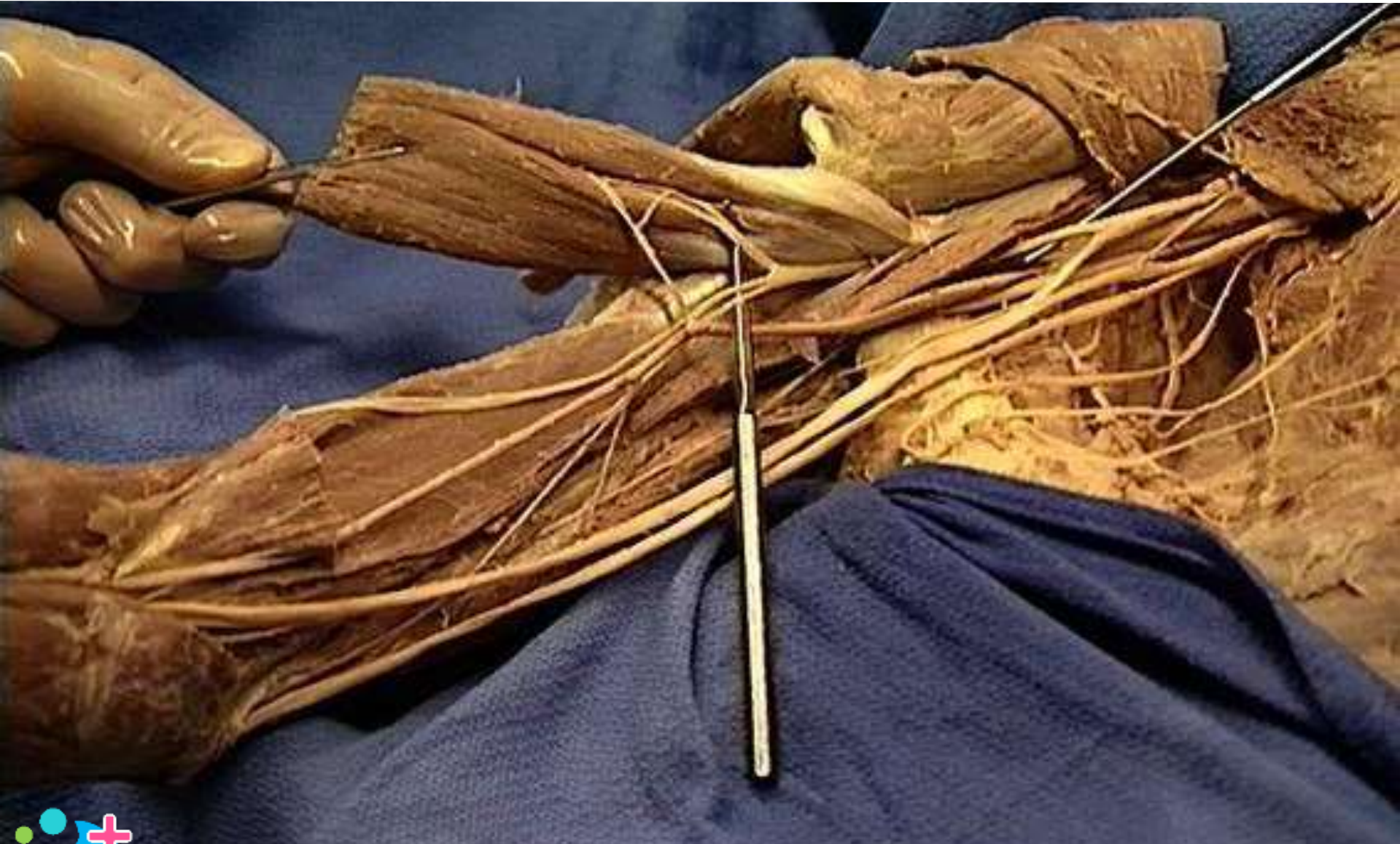Extensor expansion of finger



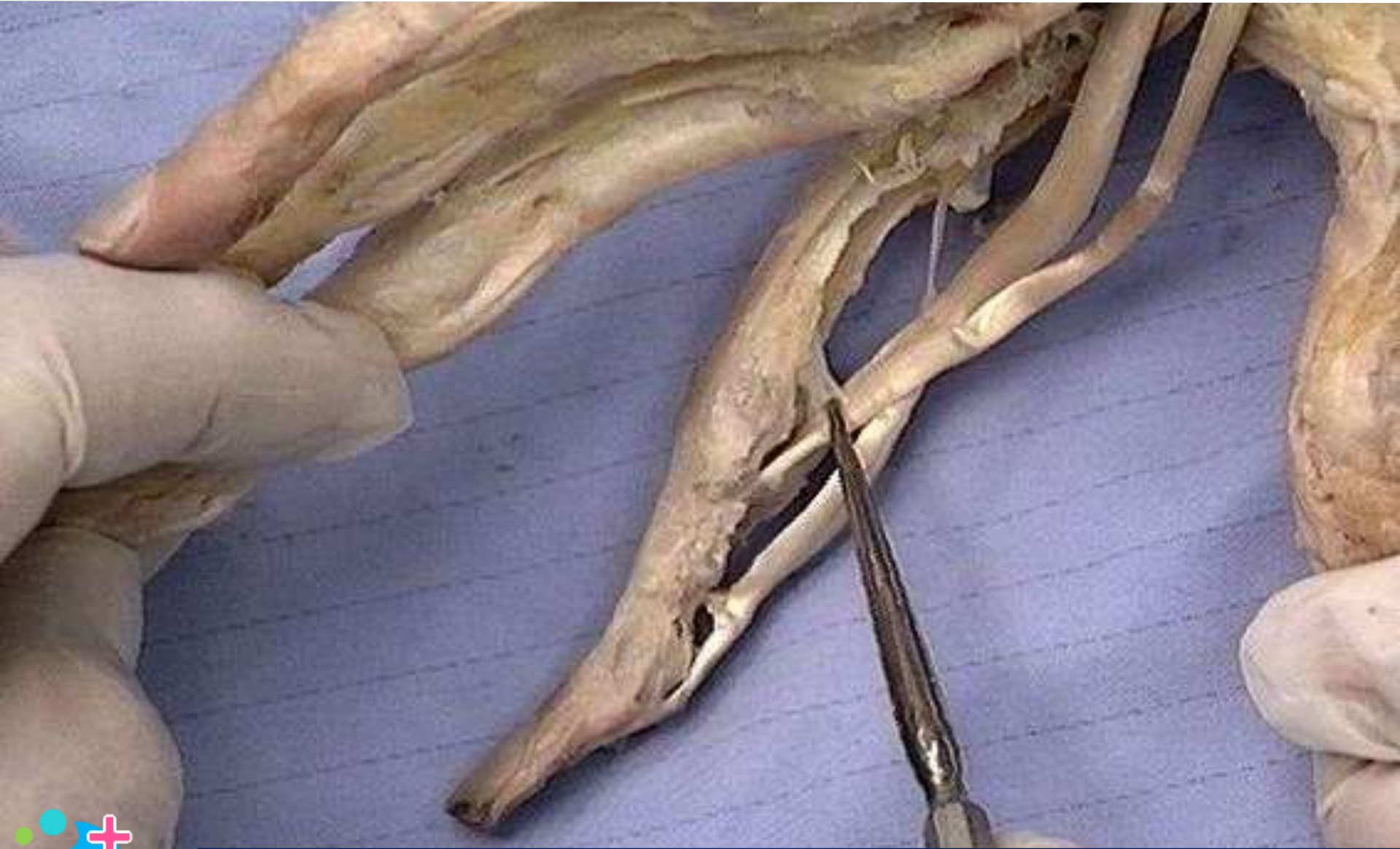
Osteofibrous compartment: 5th extensor of wrist



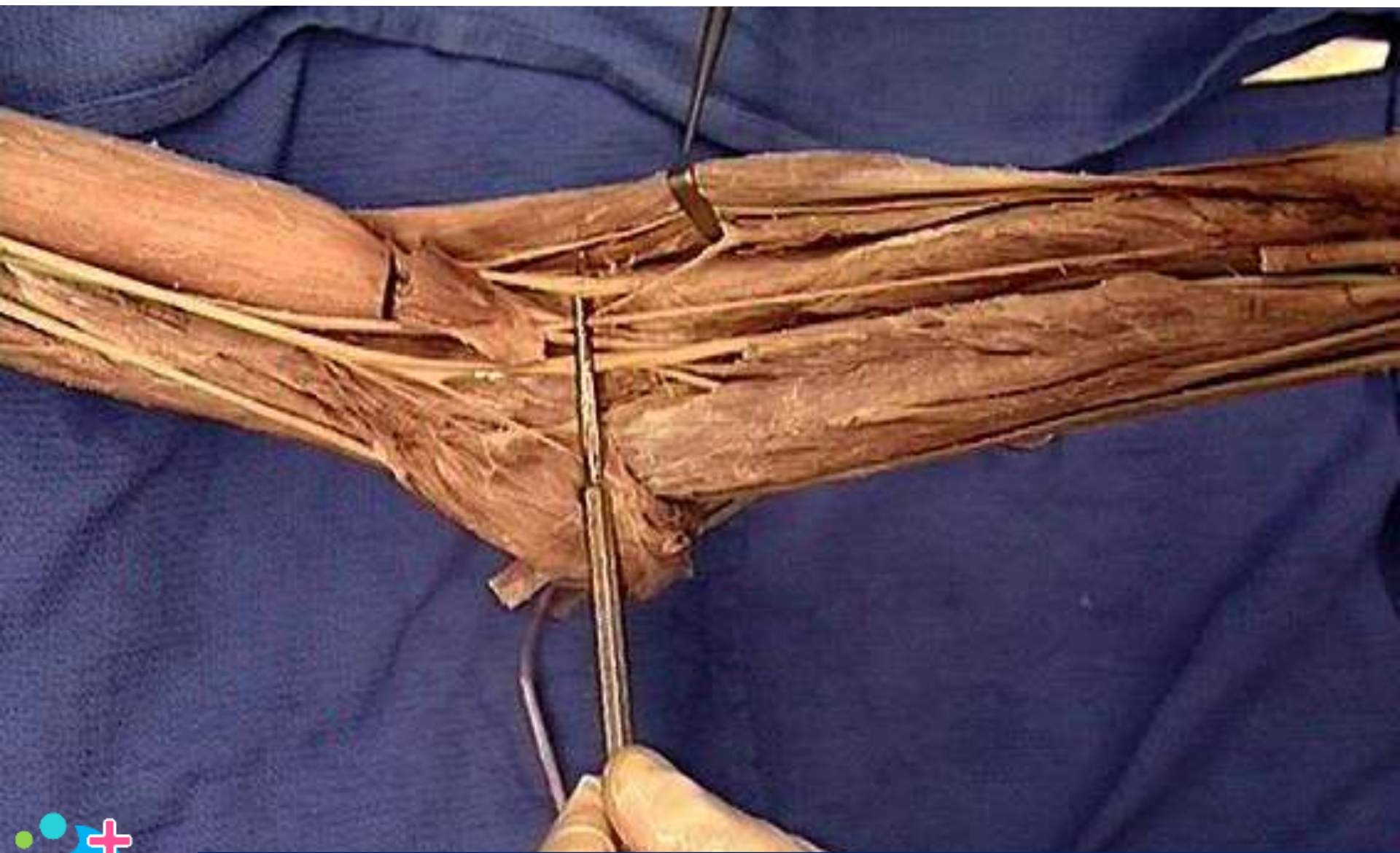
Musculocutaneous nerve



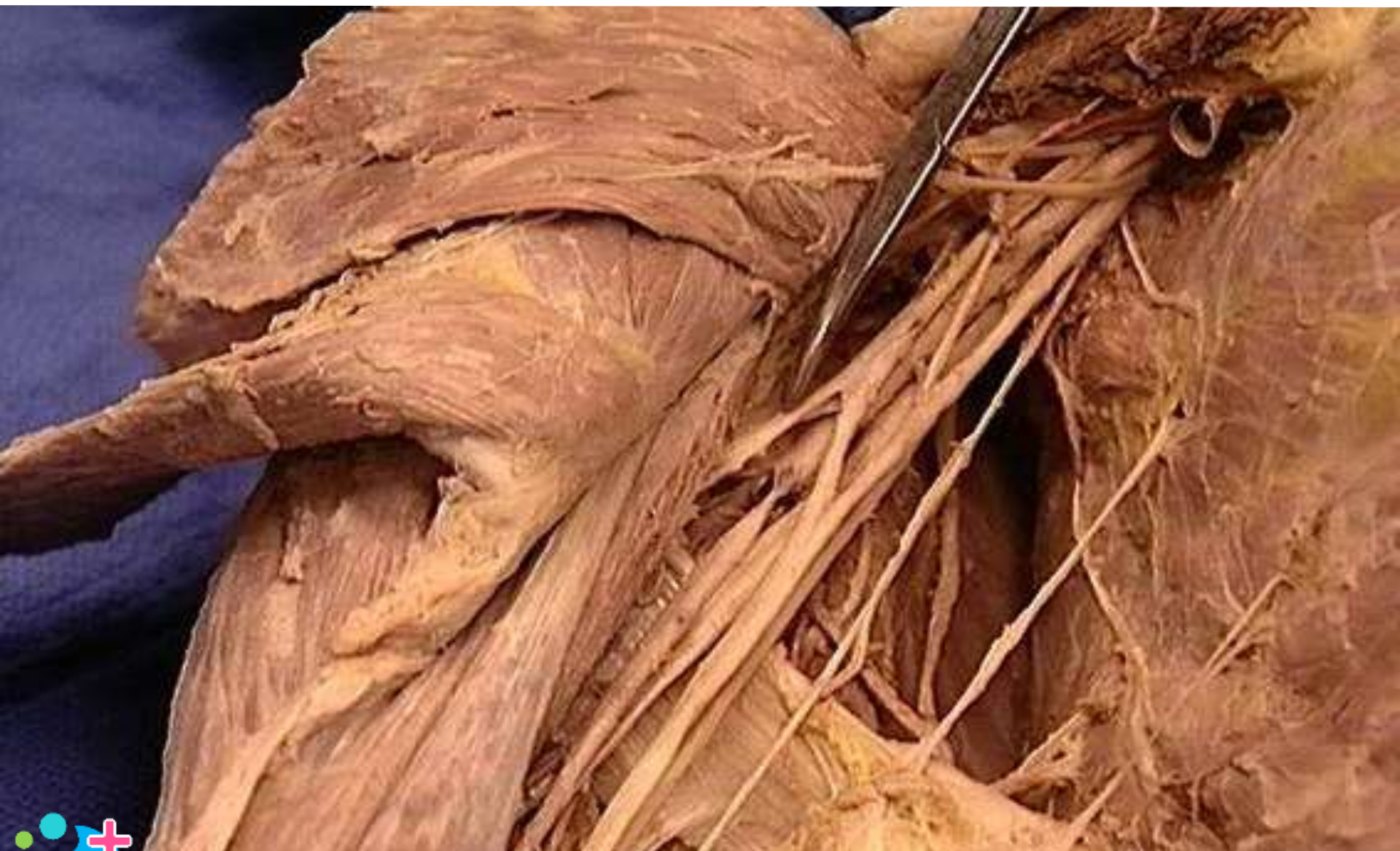Vinicula longa



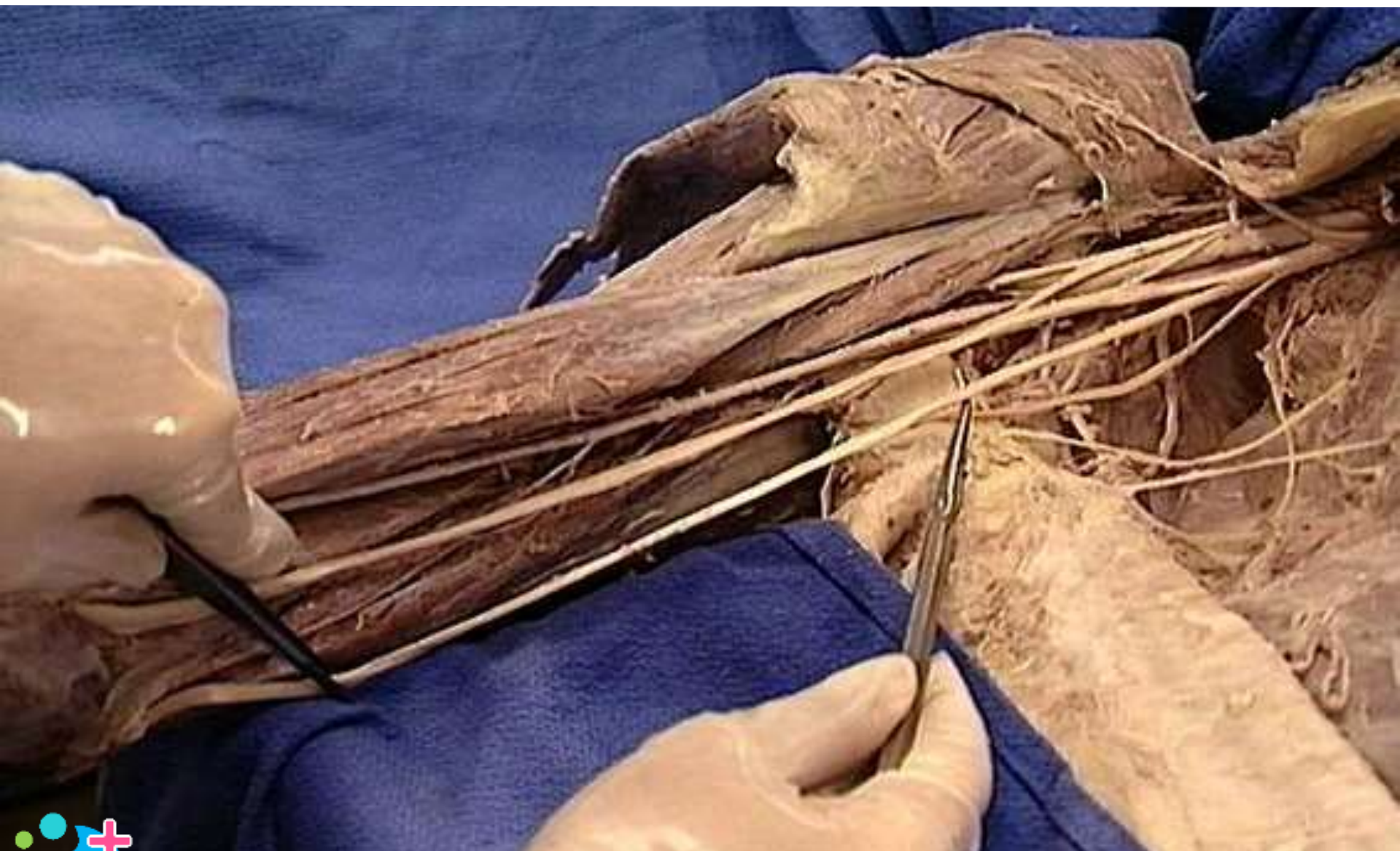
Radial nerve : deep branch



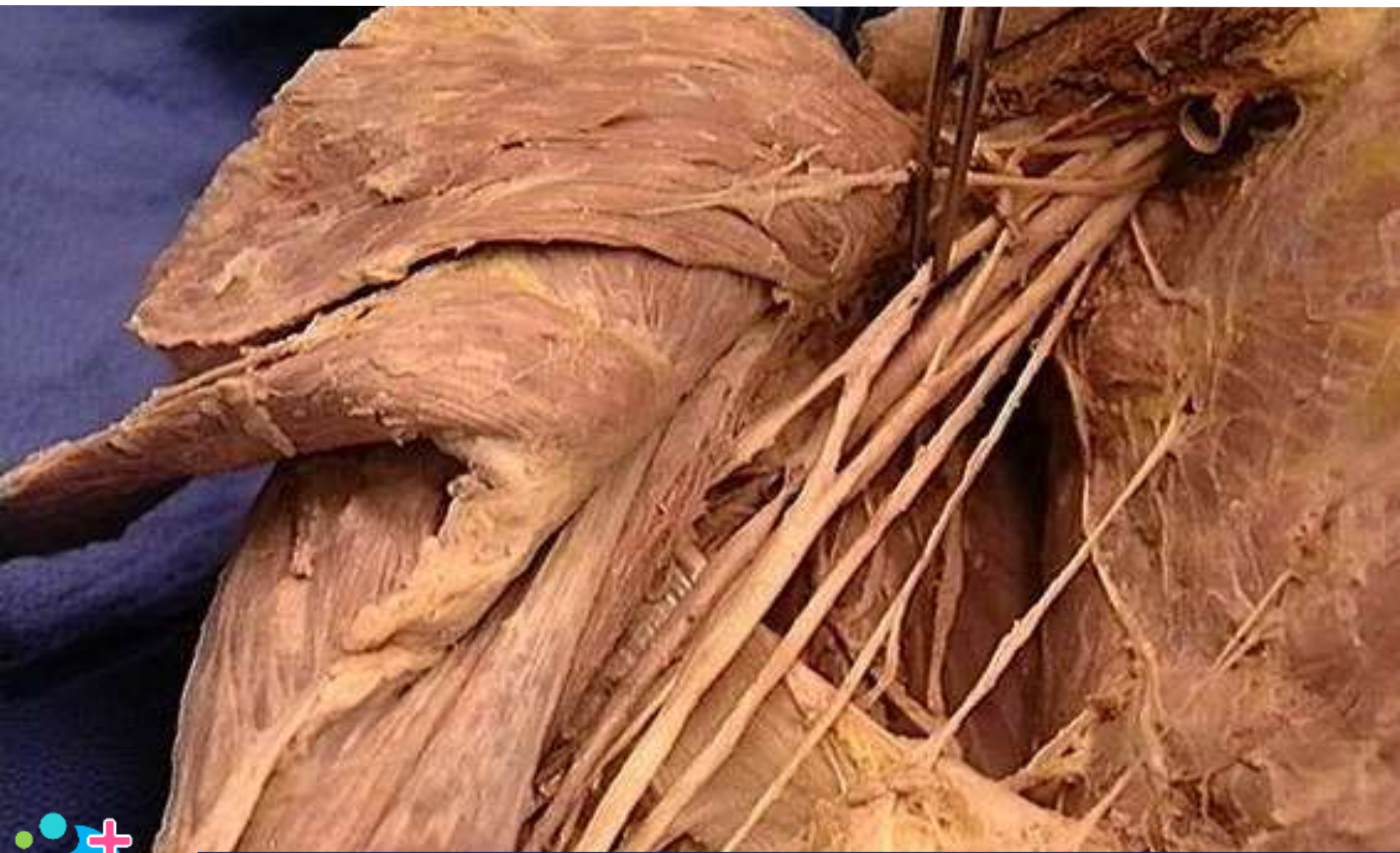Musculocutaneous nerve



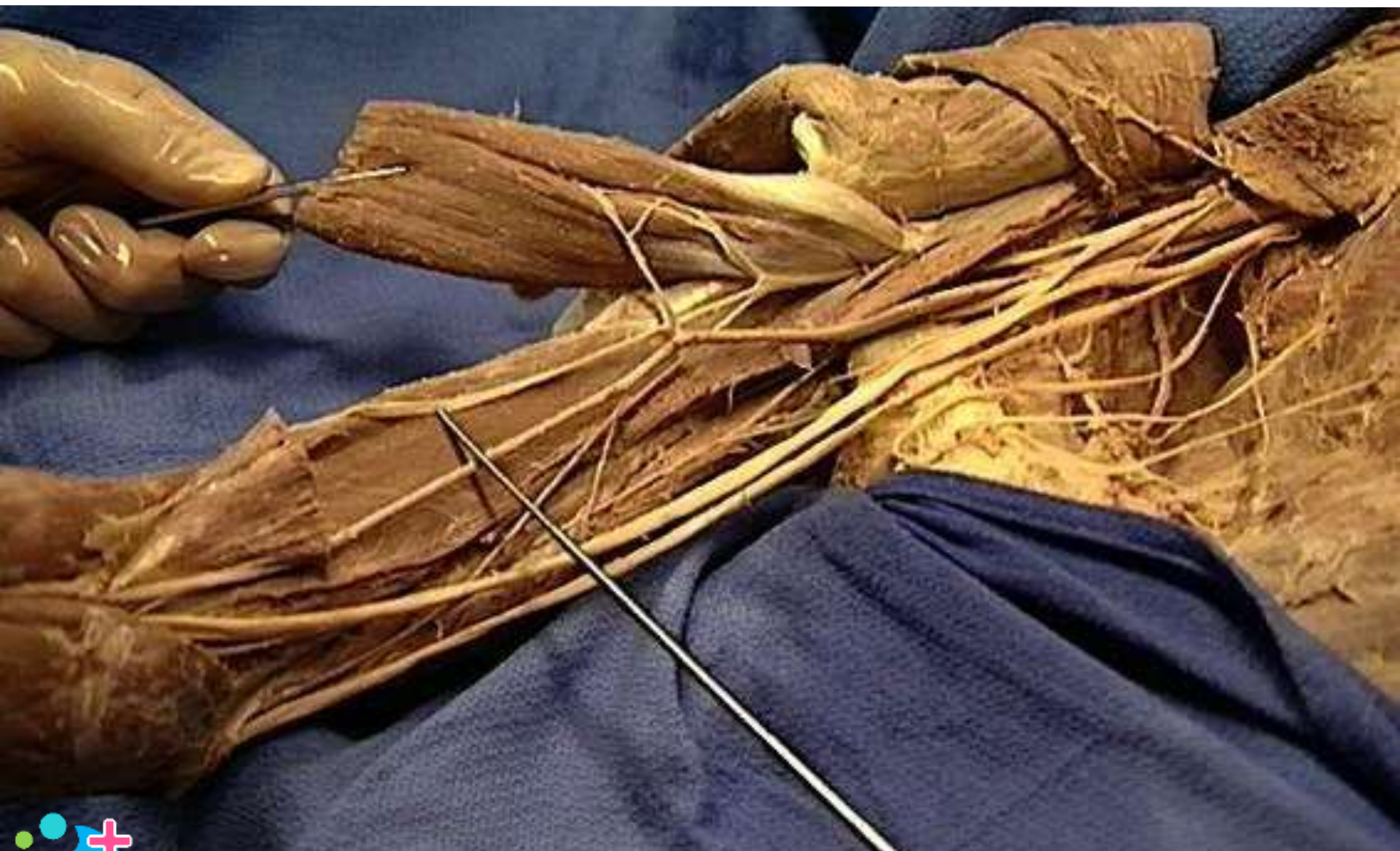Ulnar nerve



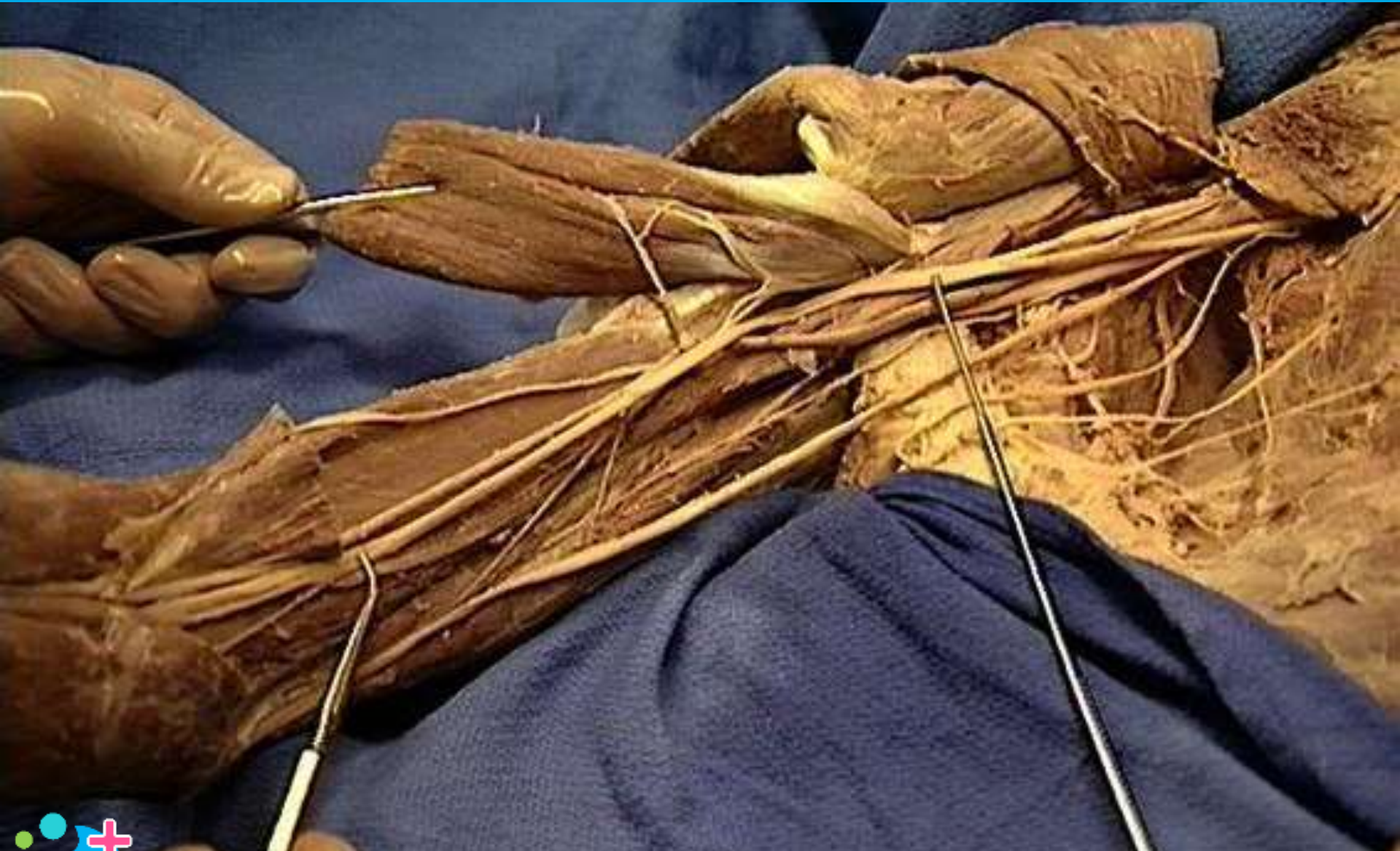Brachial plexus : lateral cord



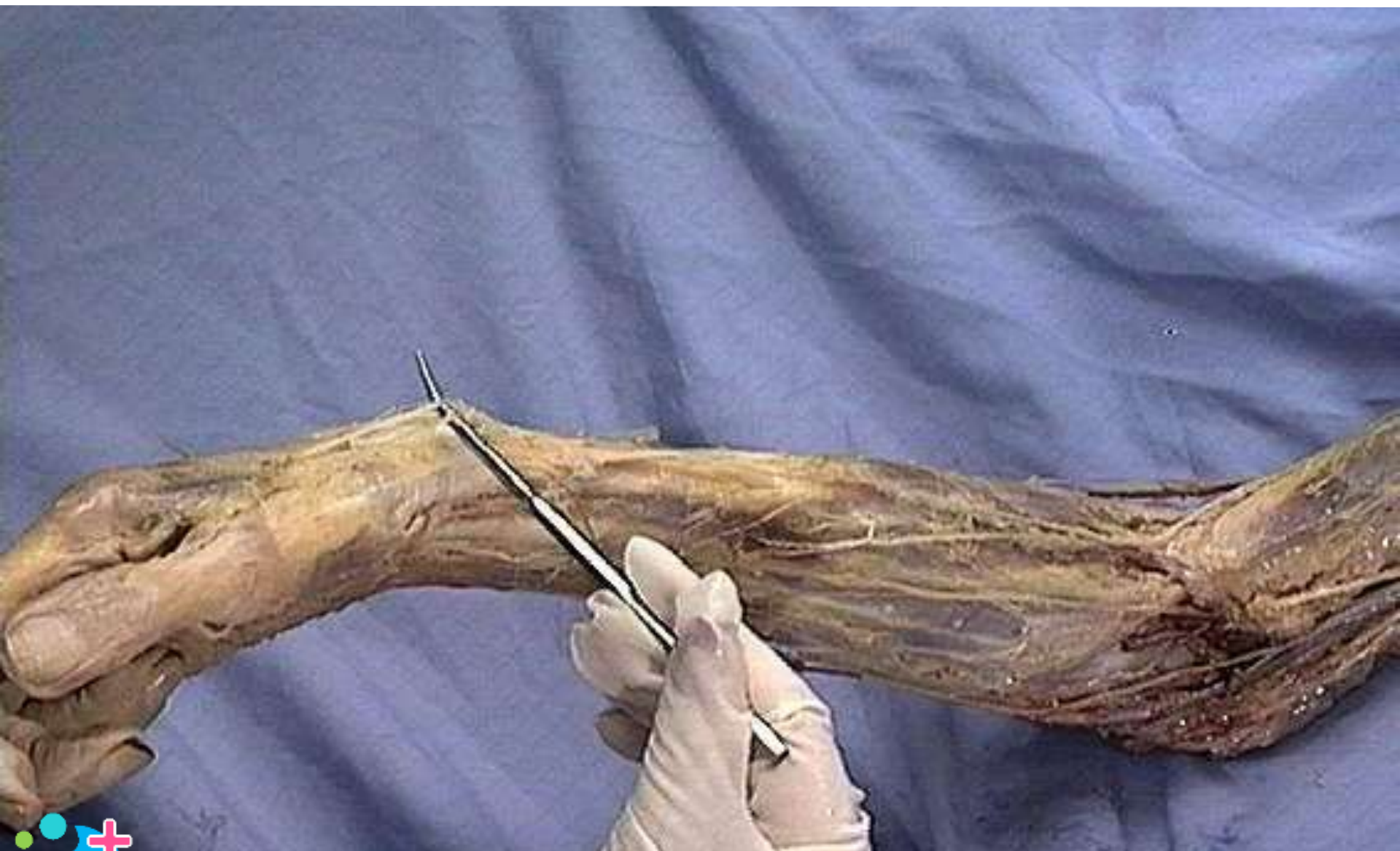Lateral antebrachial cutaneous nerve



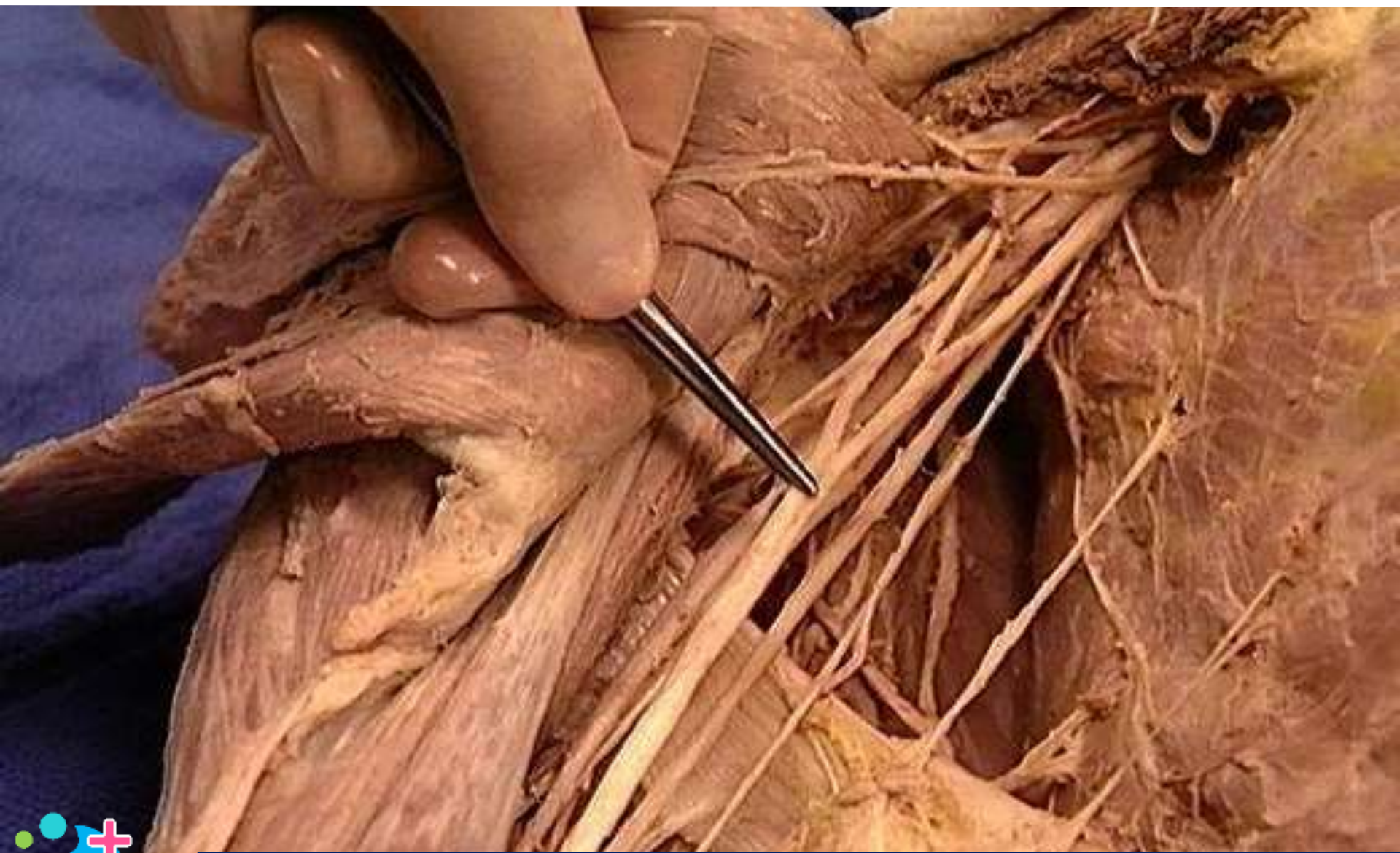Median nerve



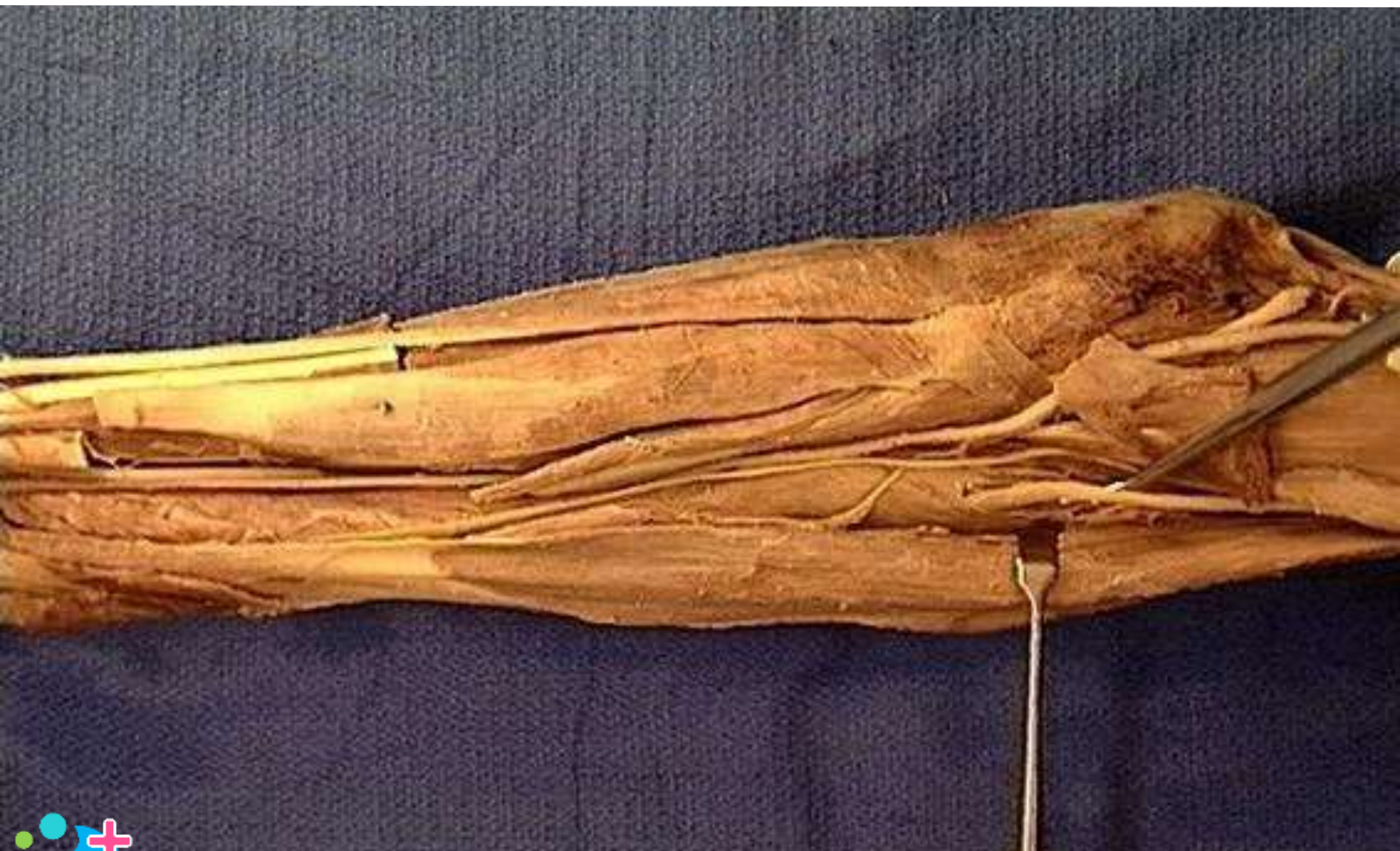Radial nerve : superficial branch



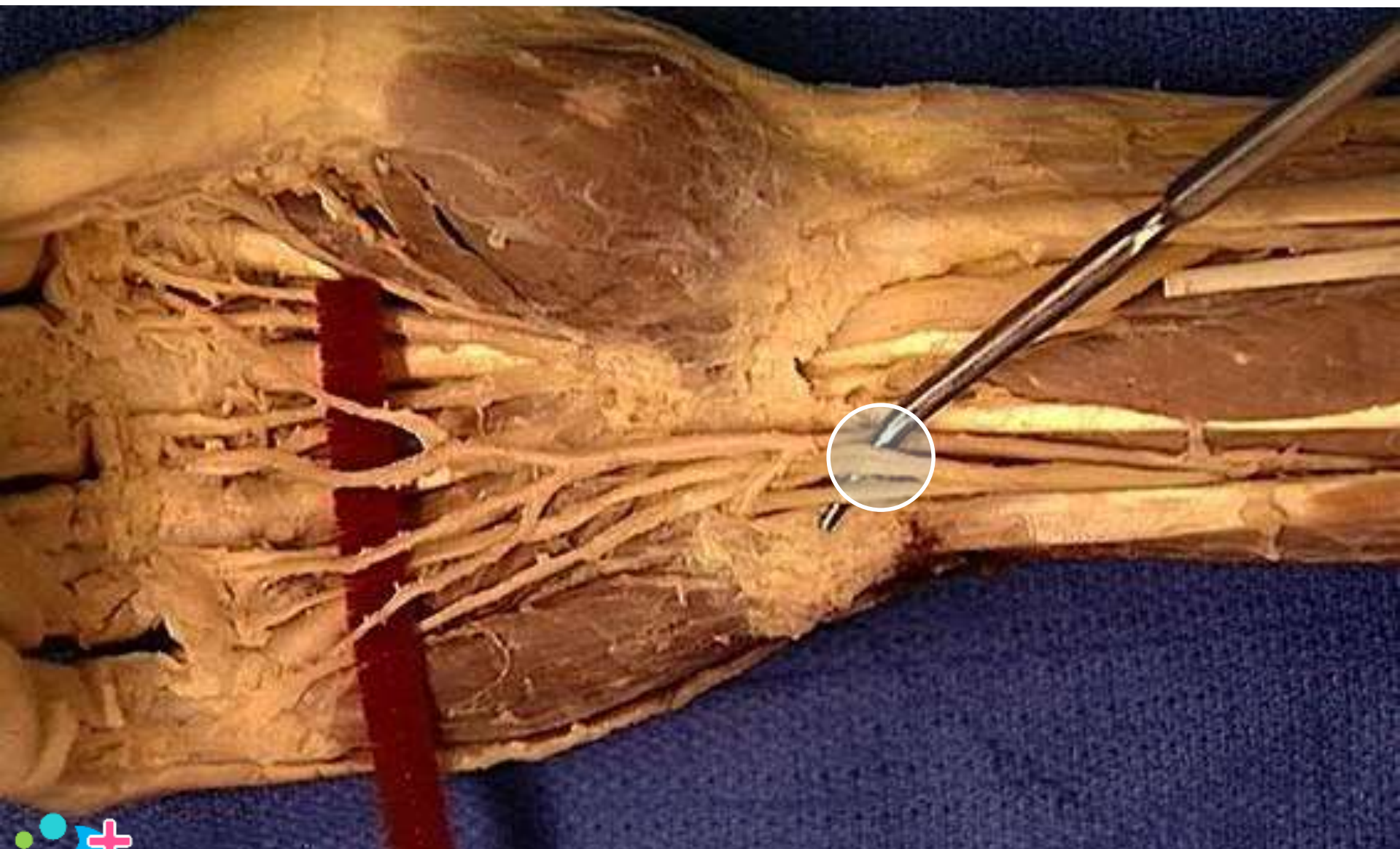
Median nerve



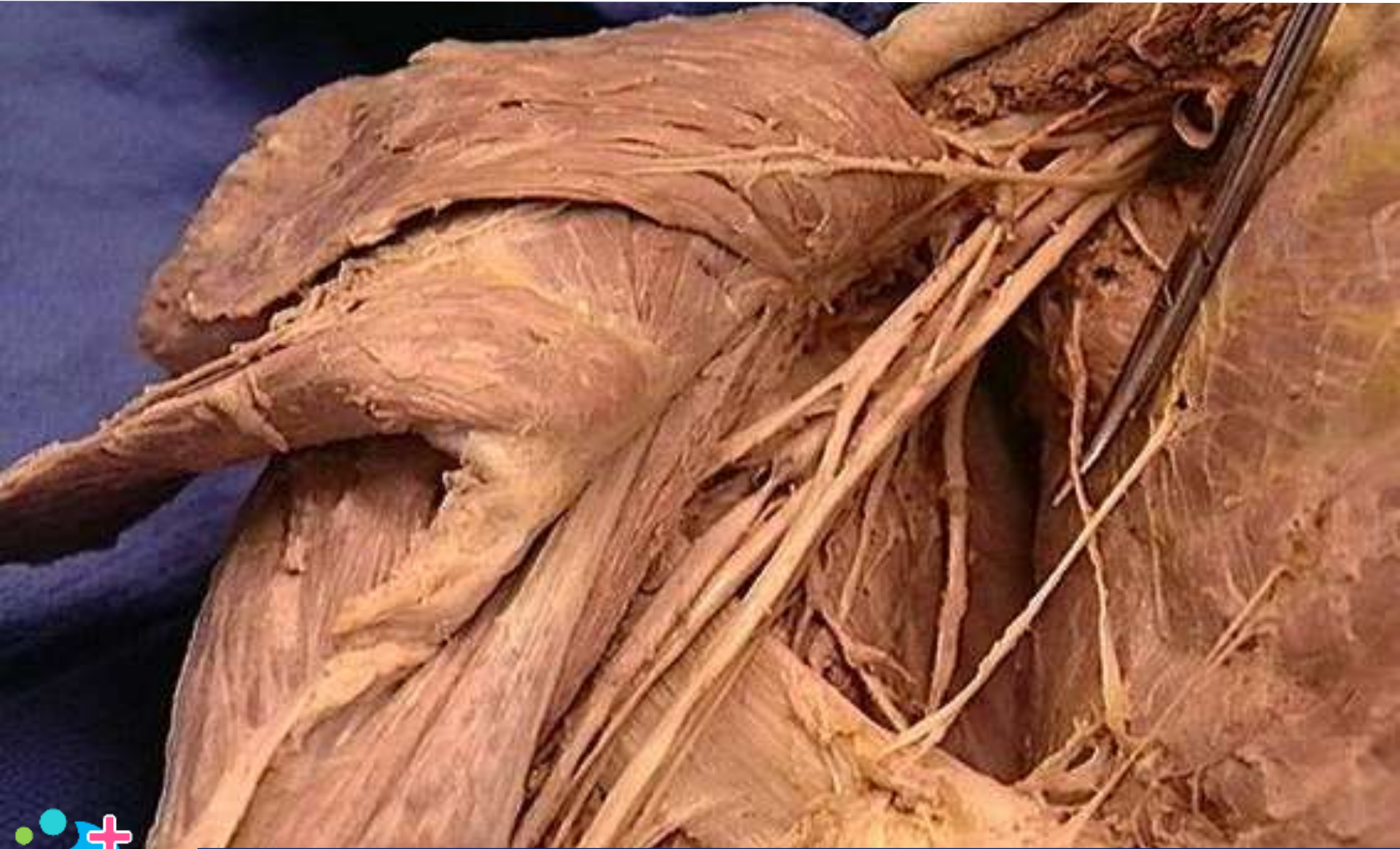Radial nerve: deep branch



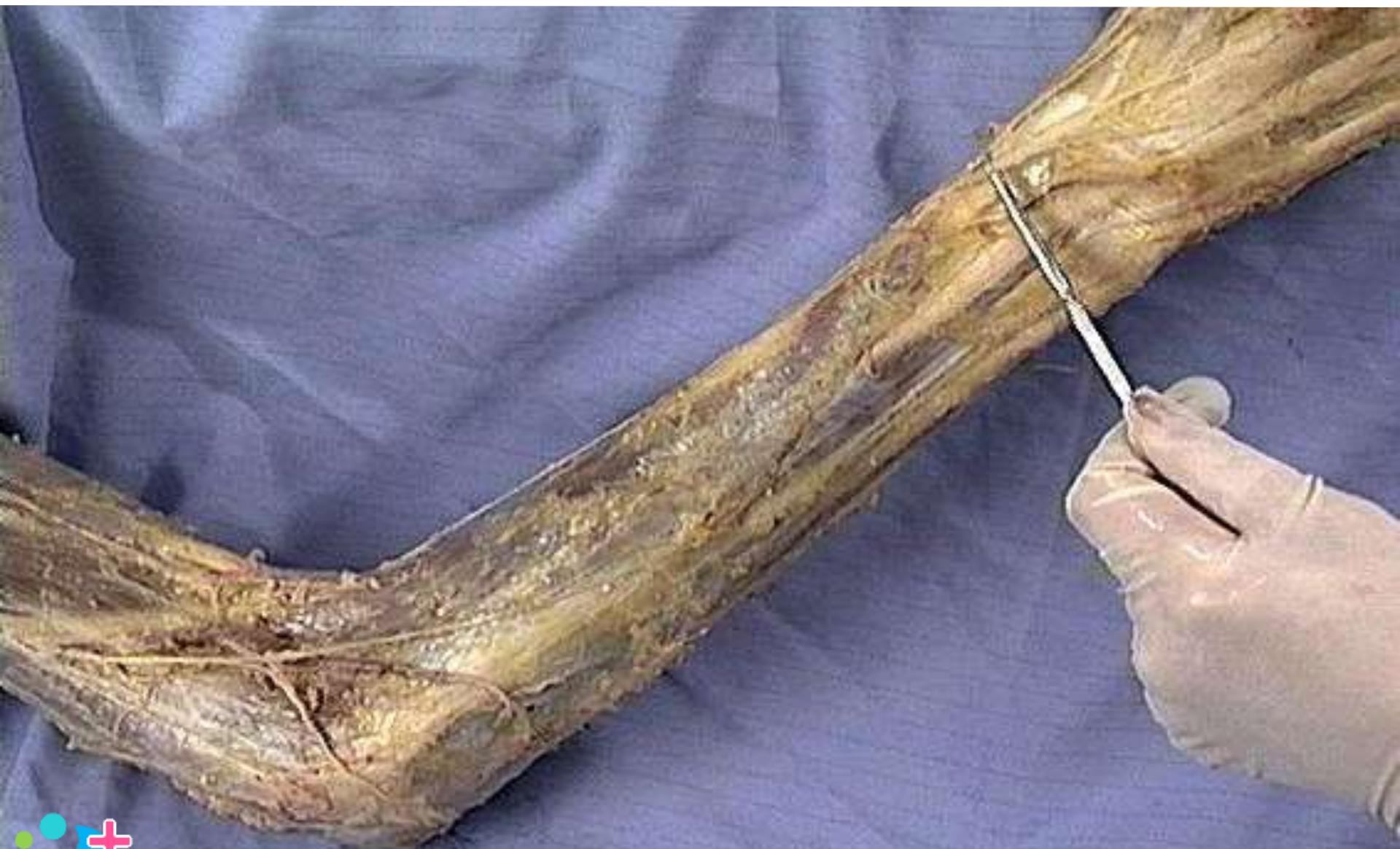Ulnar nerve



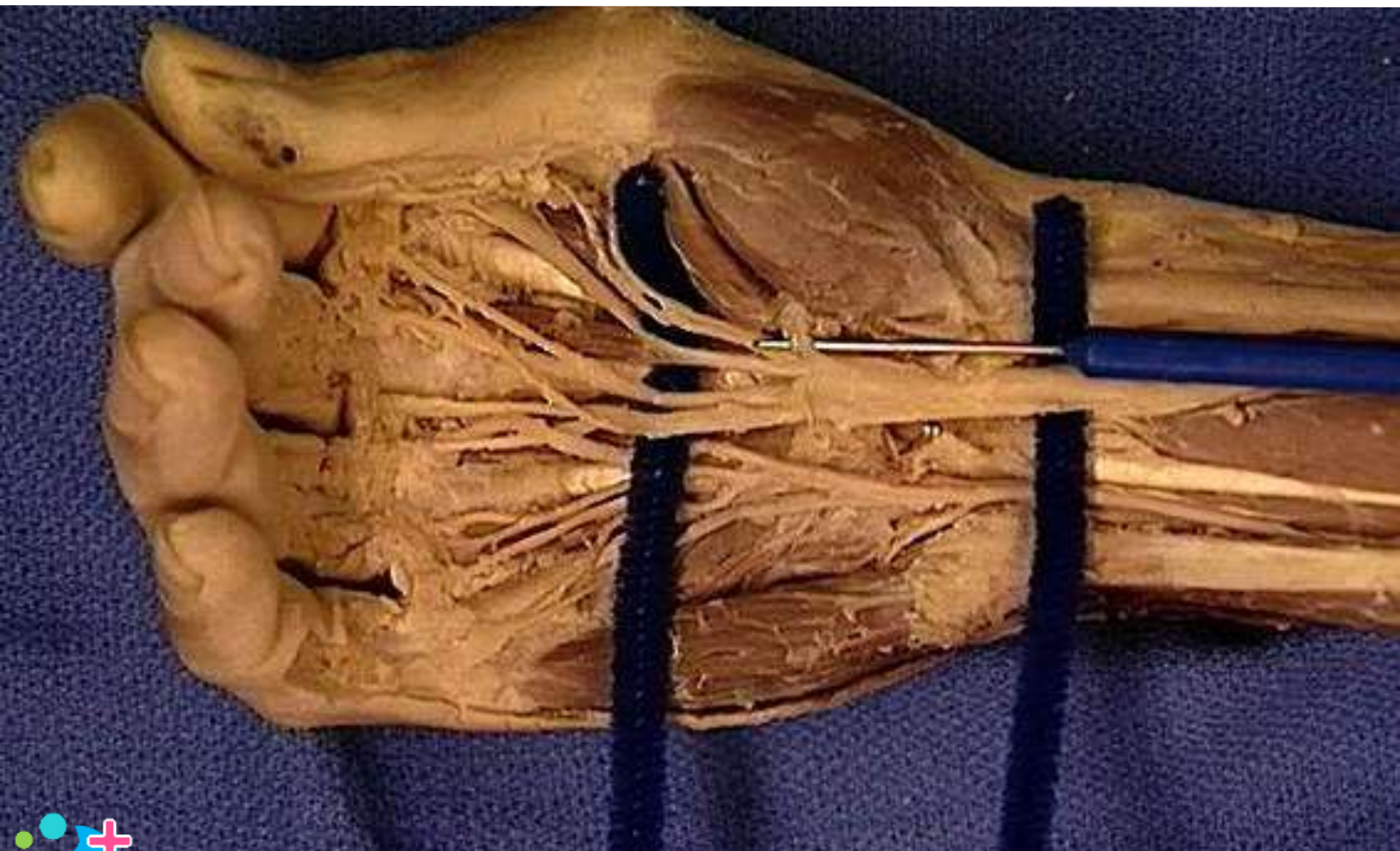
Long thoracic nerve



Radial nerve: superficial branch



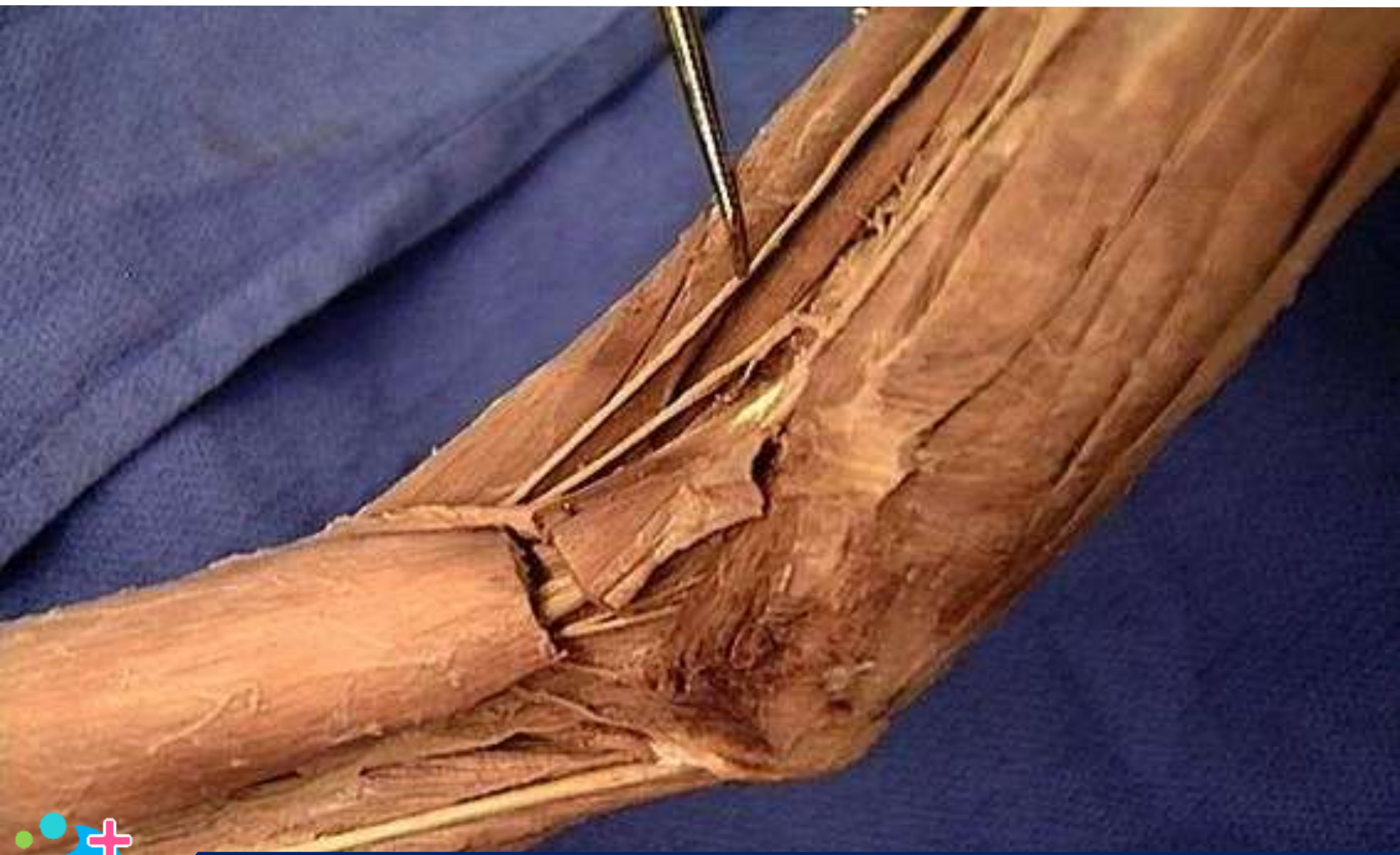Median nerve: recurrent branch



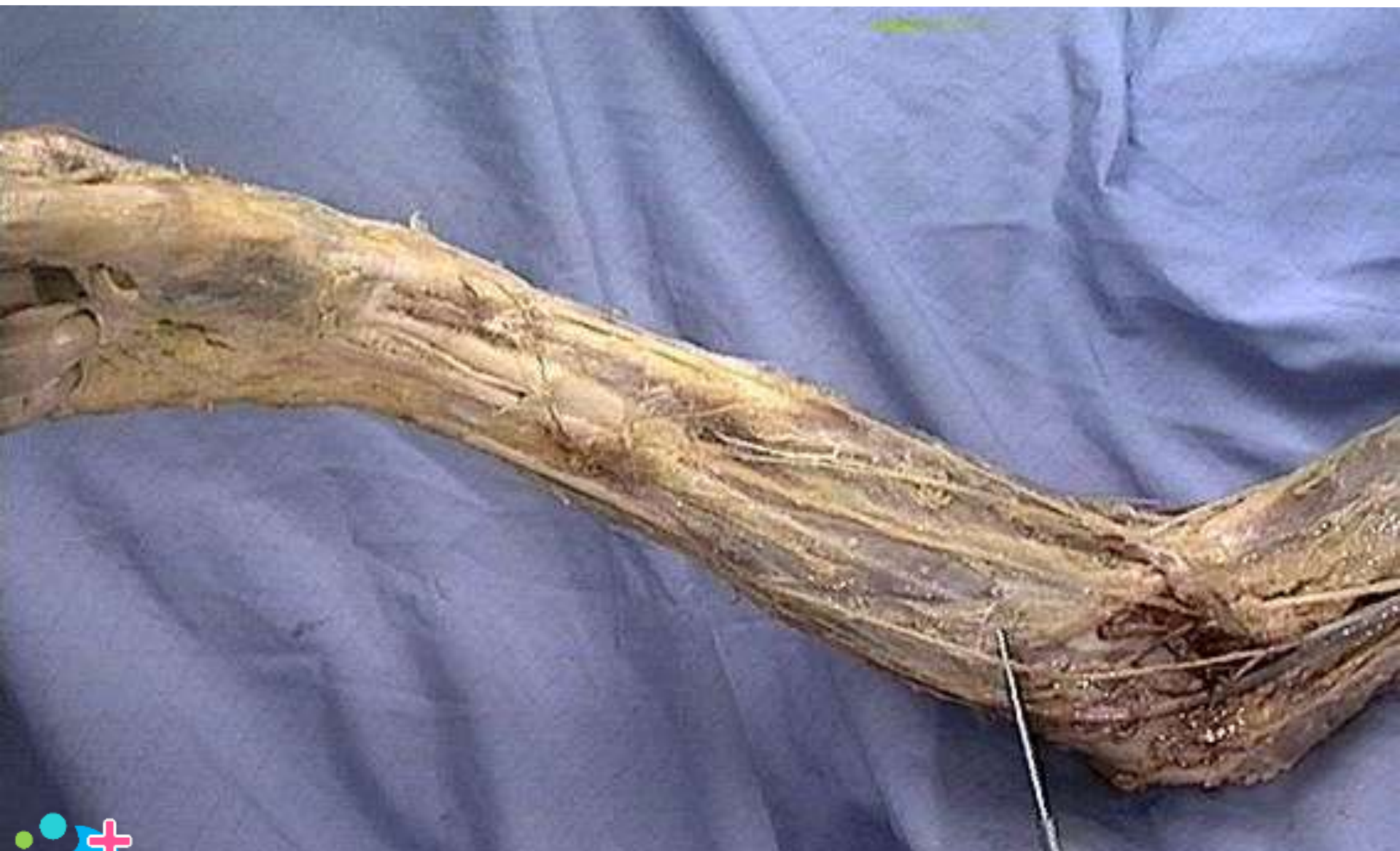Pectoral nerves



Radial nerve: superficial branch



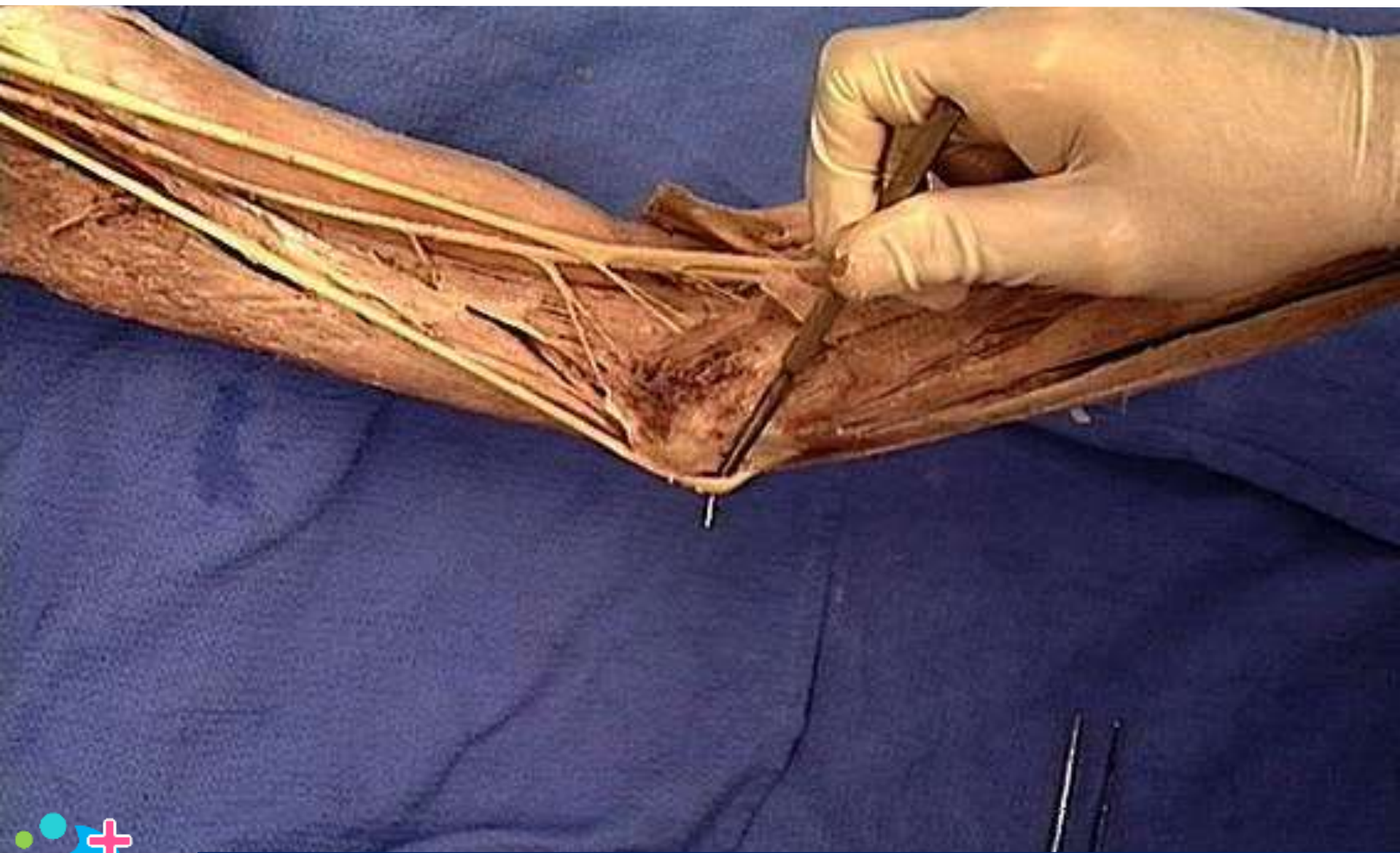
Medial antebrachial cutaneous nerve



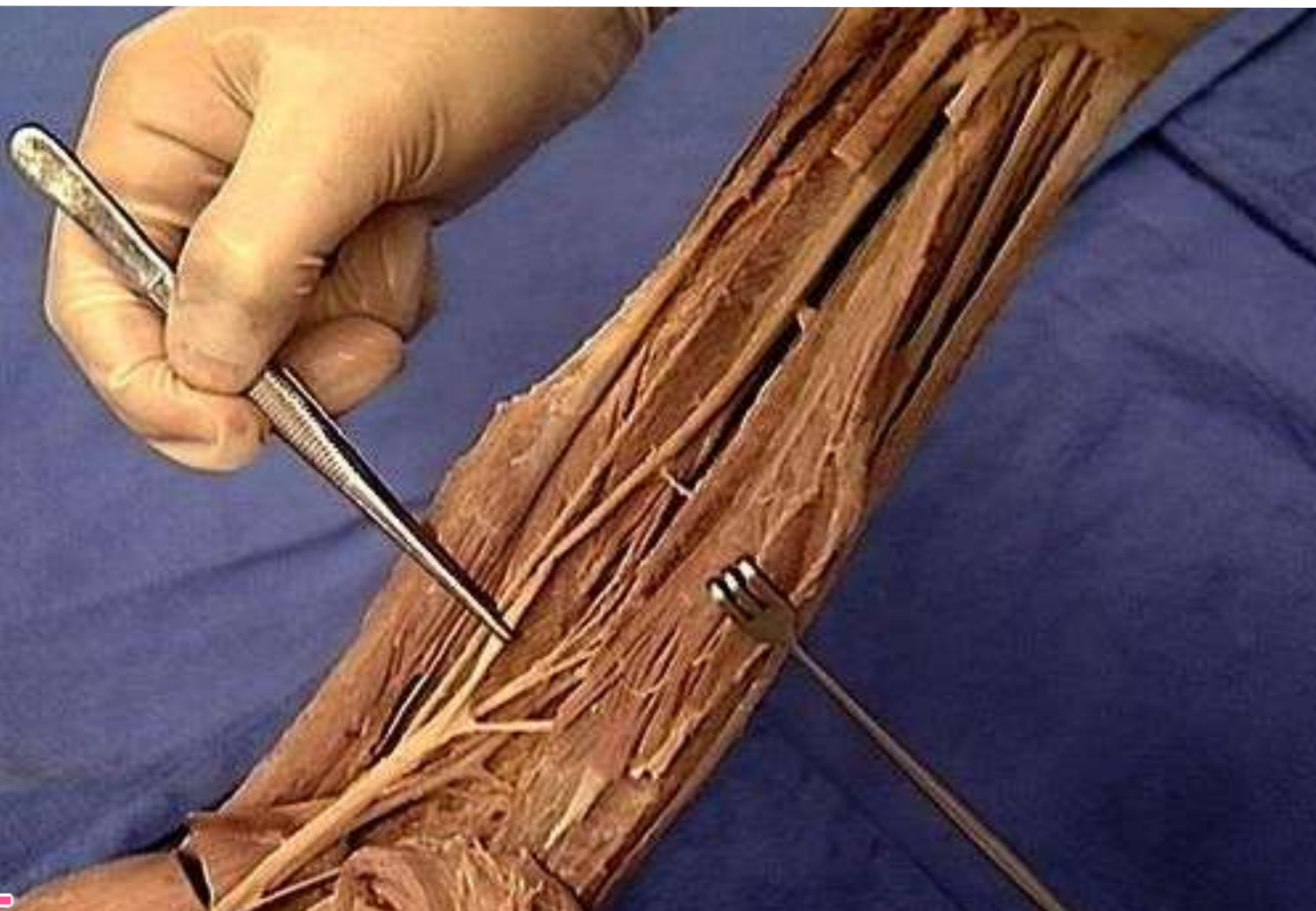
Ulnar nerve: deep branch



Ulnar nerve



Median nerve



Lower subscapular nerve

